



Clinical Anatomy, Radiography, and Computed Tomography of the Chinchilla Skull

Serena Z. G. Brenner, MS, DVM

Michelle G. Hawkins, VMD, DABVP (Avian)

Lisa A. Tell, DVM, DABVP (Avian), DACZM

William J. Hornof, DVM, DACVR*

Charles G. Plopper, DVM, PhD

Frank J. M. Verstraete, DrMedVet, MMedVet, DAVDC, DECVS

University of California, Davis

ABSTRACT: Dental disease is one of the most common clinical conditions in pet chinchillas (*Chinchilla lanigera*); however, there is little published information regarding the normal anatomy of the chinchilla skull. This article addresses the normal dentition and skeletal anatomy of the chinchilla head as well as the diagnostic dental evaluation of chinchillas, including oral examination and appropriate imaging techniques. Diagnostic imaging studies comparing normal and severe dental disease in chinchillas are included.

The anatomy of the head of many domestic lagomorphs and rodents, such as rabbits, guinea pigs, rats, mice, and hamsters, has been well described.¹ Chinchillas (*Chinchilla lanigera*) are gaining popularity as pets. Dental disease is very common in pet chinchillas, and clinical signs associated with dental disease are often the primary reason patients present to exotic animal practitioners. Knowledge of the normal anatomy and dentition as well as examination and imaging techniques of the chinchilla head is necessary for appropriate diagnosis and treatment of dental disease in this species. Several reports²⁻⁸ describing

dental disease as well as diagnostic imaging techniques and their interpretation in chinchillas have been published.

NORMAL DENTITION AND SKELETAL ANATOMY

The skeleton of the chinchilla head consists of the cranium (i.e., the skull) and the facies (i.e., facial bones, including the mandibles, but excluding the teeth).⁹ In some publications, the term *skull* is used to denote only the cranium and all bones of the upper jaw.¹⁰ In this article, the term *skull* refers to the entire skeleton of the head, including the teeth and mandibles.¹¹

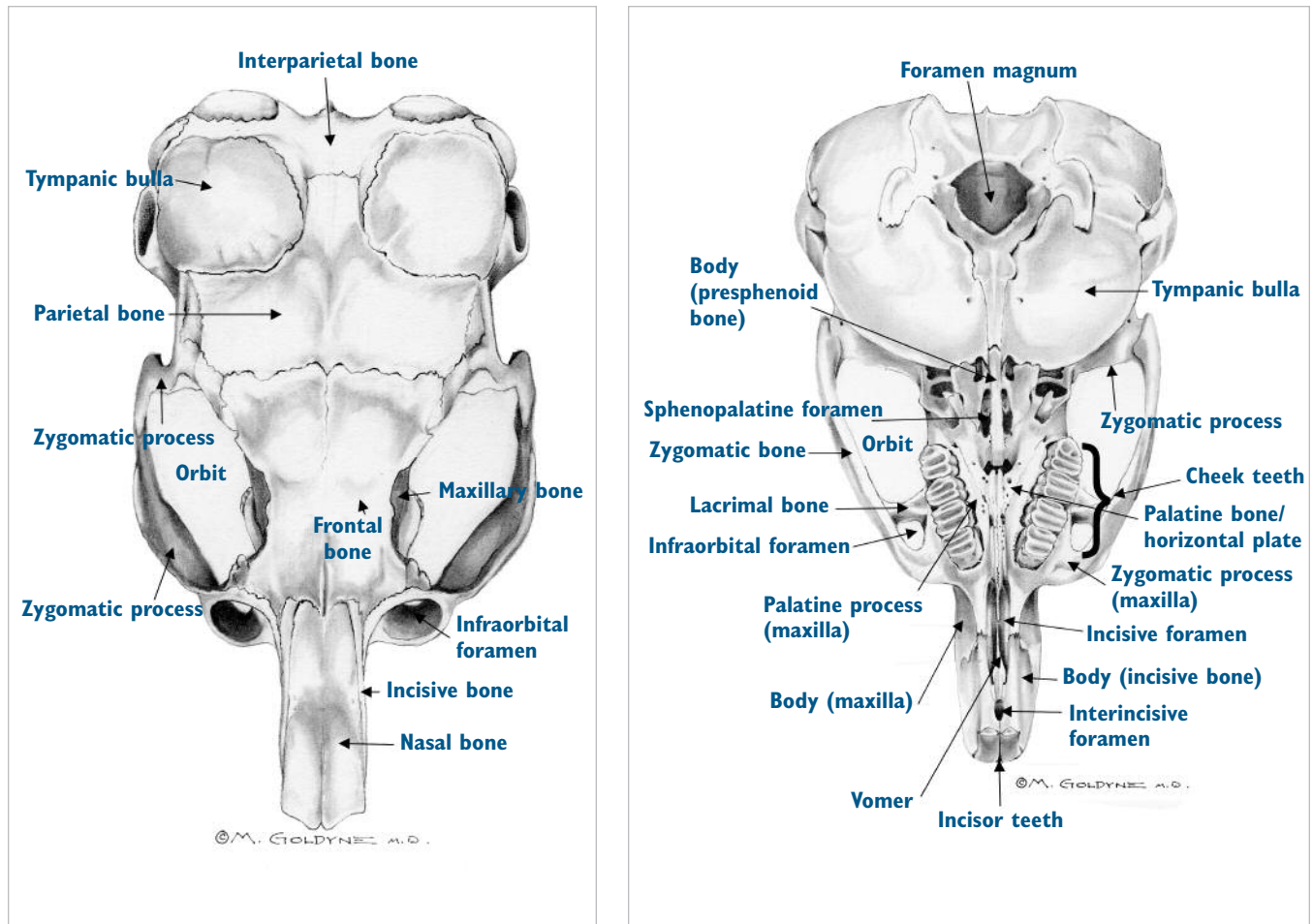
The well-developed tympanic bullae make the chinchilla skull unique compared with the skulls of other rodents. Other general differences between the chinchilla skull and the skulls of other rodents include the following in

*Dr. Hornof is currently affiliated with Elkin Medical Systems, Sunnyvale, California.

Send comments/questions via email
editor@CompendiumVet.com
or fax 800-556-3288.

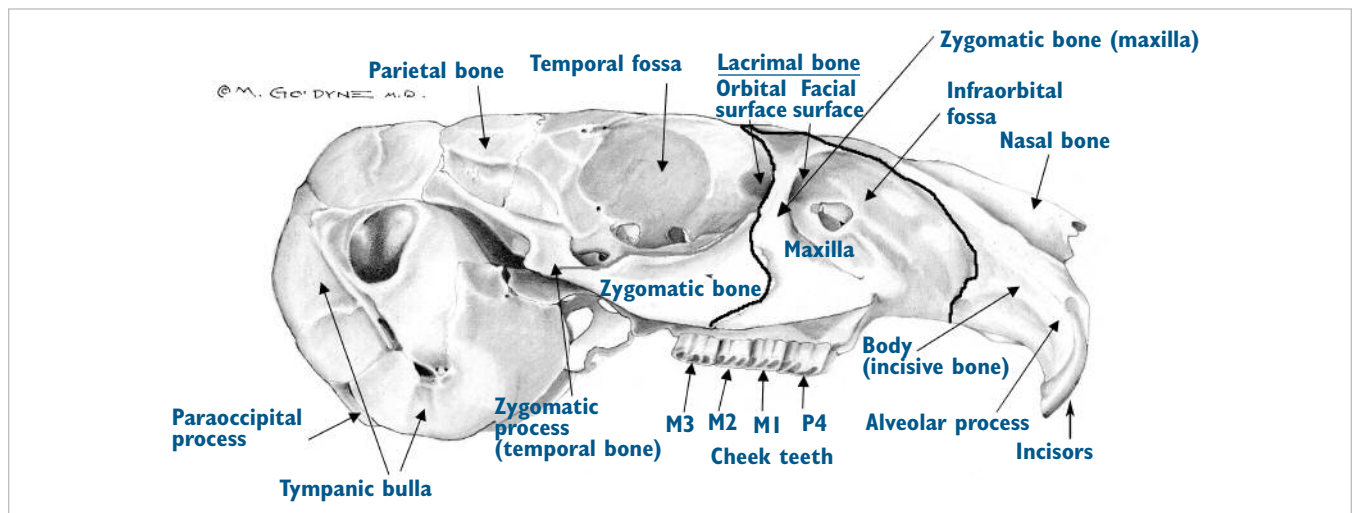
Visit CompendiumVet.com for
full-text articles, CE testing, and CE
test answers.

Figure 1. Anatomic drawing of the skull of a normal chinchilla (*C. lanigera*; the mandible is not included). (Illustrations by Marc E. Goldyne, MD, PhD)



Dorsal view.

Ventral view.



Lateral view.

chinchillas: large infraorbital foramina, reduced zygomatic arches, absence of the masseteric crest of the mandibles, large lacrimal bones, lacrimal canals that open on the side of the rostrum, and either elongated or shortened paroccipital processes^{9,12} (Figure 1). Chinchillas are herbivorous rodents with a full elodont and aradicular hypsodont dentition.^{2,4} Chinchilla teeth have long crowns with no anatomic roots and grow continuously throughout life. The term *open-rooted* is occasionally used in the literature to describe the dentition of chinchillas. However, because chinchilla teeth do not form a true anatomic root, the portion of the tooth below the alveolar margin is more correctly referred to as the *reserve crown*.⁴ The dental formula of chinchillas is $2(I\ 1/1, C\ 0/0, P\ 1/1, M\ 3/3) = 20^{3,4,12}$ (Figure 2). In contrast to rabbits, the anisognathism of the occlusion is characterized by the mandible being wider than the maxilla. As with other rodents, the occlusal planes of the premolar and molar teeth of chinchillas are slightly angled from buccal to lingual.

Normal chinchilla skulls may be purchased commercially and provide an excellent reference during dental examinations and procedures as well as evaluation via diagnostic imaging. If a normal chinchilla skull is not available, photographs of skulls representing normal anatomy and dentition can be used.

DENTAL DISEASE

Because chinchillas with dental disease often present to veterinary practices, it is important for veterinarians to be familiar with the factors that contribute to dental disease as well as with appropriate preventive measures, diagnostic techniques, and treatment options. Dental disease may be attributed to both husbandry and genetics. The relative contribution of each has not been sufficiently researched, but correcting poor husbandry and avoiding the breeding of chinchillas with

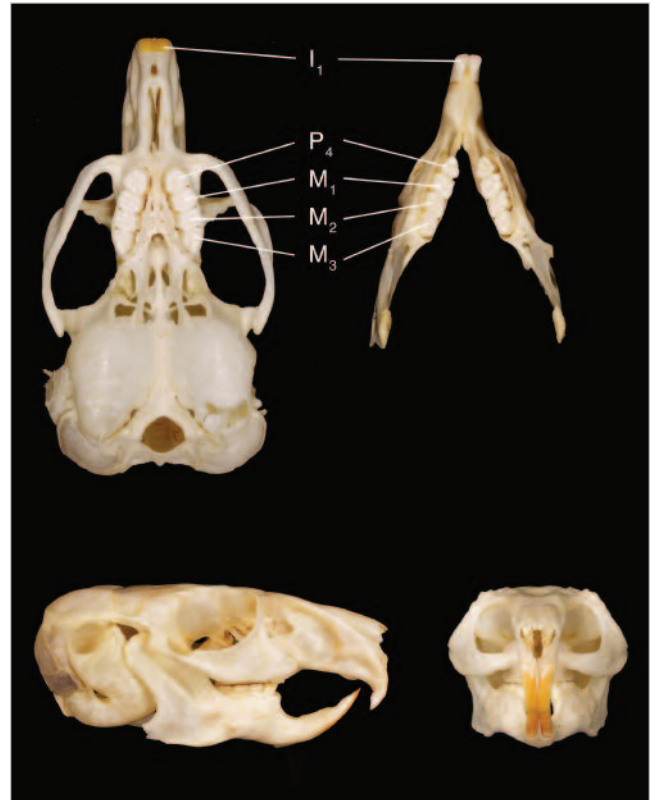

Figure 2. Normal dentition of a chinchilla (*C. lanigera*). Clockwise from top left: Occlusal view of the upper jaws; occlusal view of the mandibles; frontal view; lateral view, illustrating the angle of the occlusal plane between the premolars and molars. (Reprinted with permission from Verstraete FJM: Advances in diagnosis and treatment of small exotic mammal dental disease. *Semin Avian Exot Pet Med* 12:37–48, 2003)

fore extremely important to provide a varied diet in captivity to maintain a physiologic tooth length to reduce the potential for malocclusion.^{2,3,5,7}

Many chinchilla caretakers do not provide adequate dietary variety to maintain appropriate tooth length and

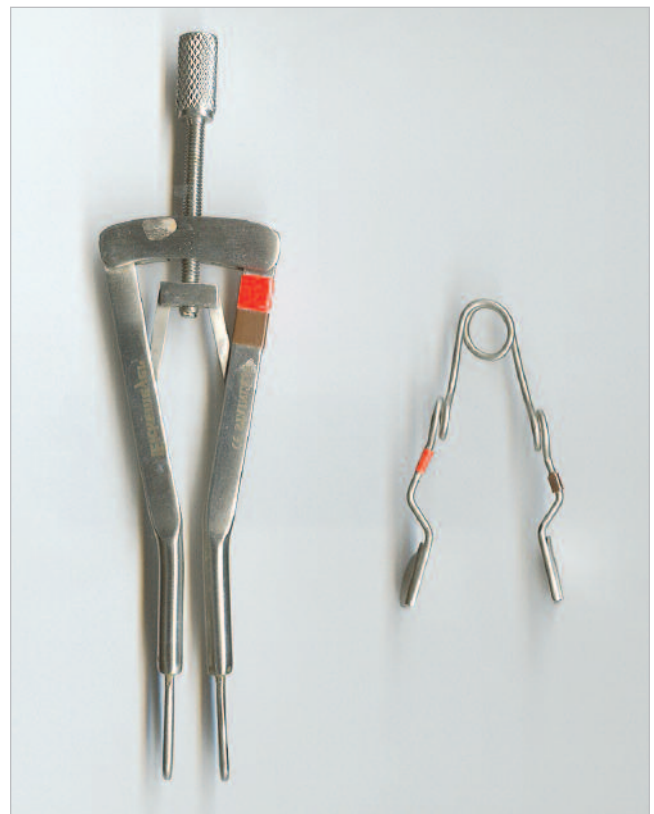An appropriate diet is important in preventing dental disease in chinchillas.

diagnosed dental disease appear to reduce the incidence of dental disease.^{3,8,13} In the wild, seasonal changes in tooth length have been observed based on available forage.⁴ When comparing clinically normal wild chinchillas with captive-bred animals, it was found that the latter had 35% longer premolars and molars, suggestive of early dental disease.⁴ It is there-

occlusion. Early accounts by the first fur trappers noted that wild chinchillas ate roughage, including wild grasses found at high elevations in semiarid conditions.^{14,15} The chinchilla's well-developed cecum is further evidence of a wild diet primarily consisting of roughage. Dietary roughage in captivity is provided by pellets (16% to 20% crude fiber, <18% to 20% crude

Figure 3. Equipment used for oral examination of chinchillas.

Bivalve nasal speculum (top) and otic specula in 4-, 5-, and 6-mm diameter sizes (bottom).



Rodent incisor speculum (left) and pouch dilators (right).

protein, <3% crude fat), hay (i.e., timothy, grass, or oat), and fresh vegetables and greens. Fruit should be considered a treat and not part of the dietary roughage because of its high sugar content.¹³⁻¹⁷ Hay should be the primary food source and should be provided ad libitum. Chinchilla pellets should be offered at 2 to 3 tbsp/day per chinchilla. Fresh greens and vegetables should be provided at no more than 15% of the total daily diet, and fecal consistency should be monitored. If the feces become soft, the type and frequency of greens should be evaluated. The efficacy and safety of chew toys and other gnawing substrates have not been studied. However, one author (S. Z. G. B.) has been heavily engaged in breeding this species for more than 20 years and anecdotally reports that gnawing substrates may help maintain appropriate tooth length.

Malocclusion can be characterized by uneven or malaligned occlusal surfaces of the cheek teeth premolars and molars and/or overgrown incisors. If malocclusion remains untreated, the maxillary premolars and

molars continue to grow in a buccal direction and the mandibular premolars and molars in a lingual direction. In addition to intraoral elongation of these teeth, the cheek teeth can also elongate in an apical direction. The incisors may become elongated as a result of the elongated premolars and molars, thereby preventing physiologic mouth closure. Elongation is caused by abnormal anisognathism or disparity between growth, eruption, and/or attrition rates of premolars, molars, and/or incisors.^{3,4,6} A patient with these abnormalities can be asymptomatic during the initial phases of the disease and then progress to exhibiting clinical signs such as ptyalism, weight loss, dysphagia, ocular discharge, palpable maxillofacial or mandibular bony swelling, and changes in fecal consistency. Clinical signs and a thorough physical examination alone are often unreliable in making a complete assessment of dental abnormalities of the chinchilla; diagnostic imaging is often necessary to establish an accurate treatment plan and prognosis.⁵

DIAGNOSTIC EVALUATION OF DENTAL DISEASE

Oral Examination

Because many chinchilla caretakers do not provide adequate dietary variety to maintain appropriate tooth length and occlusion, annual or biannual oral examinations to detect early dental abnormalities are recommended. Thorough extraoral and intraoral examinations are important components of the complete physical examination of chinchillas. The extraoral examination can be performed in most awake patients and should always include evaluation of the symmetry of the head, maxillofacial palpation, evaluation of the incisor and premolar/molar occlusion (i.e., bite), observation of masticatory movement, and evaluation of the lips and cheeks for anatomic defects or trauma. Maxillofacial palpation includes evaluation of the mandibular/sublingual glands, mandibular lymph nodes, zygomatic arch, maxilla, orbit, mandibles, and temporomandibular joints. It is extremely important to have an appreciation of the normal palpation of the ventral surface of the mandible and lateral aspect of the maxilla because slight variations in bony protuberances on these surfaces may indicate dental disease. We recommend obtaining a normal chinchilla skull to use as a reference.

A cursory intraoral examination can be performed in awake patients with the aid of a lighted bivalve nasal speculum or an otic speculum (Figure 3). The nasal speculum offers the ability to dilate the cheeks to provide a wider field of view; however, because the speculum is metal, there is a risk of injury to the teeth and soft tissues if the chinchilla bites the speculum. Otic

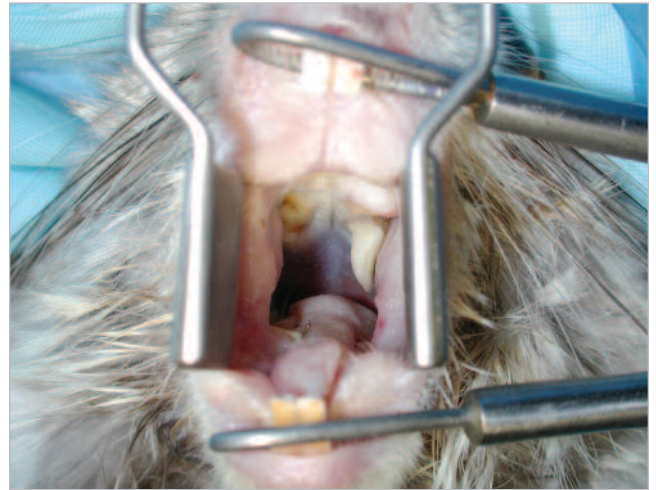

Figure 4. Oral examination of a chinchilla under general anesthesia, with the incisor speculum and pouch dilator in position. Note the severely elongated left maxillary fourth premolar.

incisor speculum should be placed on the upper and lower incisors and then widened slowly, using gentle traction and taking care not to overextend the temporomandibular joints or to place excessive force on the incisors. The cheek pouch dilators are commercially available in various sizes; the smallest size should be used in chinchillas. The dilators should be gently inserted into the oral cavity to widen the cheeks, thereby allowing optimal visualization. Care should be taken not to traumatize the oral mucosa during placement of the cheek dilators. Once the patient has been properly positioned for the oral examination, residual food particles

A complete oral examination, including both intraoral and extraoral examinations, coupled with a thorough history of the diet are crucial in identifying dental disease in chinchillas.

specula are made of plastic, thus reducing the risk of injury to the teeth, but the field of view is reduced and the specula require more frequent replacement. A complete intraoral examination can be challenging in awake patients because of the small size of the chinchilla's mouth opening, long tongue, and narrow oral cavity. To perform the most thorough intraoral examination, the patient should be anesthetized or deeply sedated.

An incisor speculum and pouch dilator designed for rodents can be used to achieve better oral cavity visualization in anesthetized patients (Figures 3 and 4). The

within the oral cavity should be removed using cotton-tip applicators. In our opinion, food should be withheld 2 to 4 hours before an oral examination in which a patient is anesthetized.

Many clinicians use a tabletop rodent dental restraint device to aid in oral examination and occlusal correction of anesthetized chinchillas. This type of device allows clinicians to place a chinchilla's upper and lower incisors on the speculum portion of the device. The clinician can then widen the speculum. The platform on which the chinchilla lies can then be adjusted from a 0°

Dentistry & Oral Surgery Service
 Veterinary Medical Teaching Hospital
 University of California, Davis

Clinician:
 Student:
 Date:-.....-.....

Dental Record: Chinchilla

ORAL EXAMINATION:

Extraoral findings:

 Oral soft tissues:

TREATMENT:

- Tooth height reduction / occlusal adjustment premolars & molars
- Tooth height reduction / occlusal adjustment incisors
- Extractions:
- Other/comments:

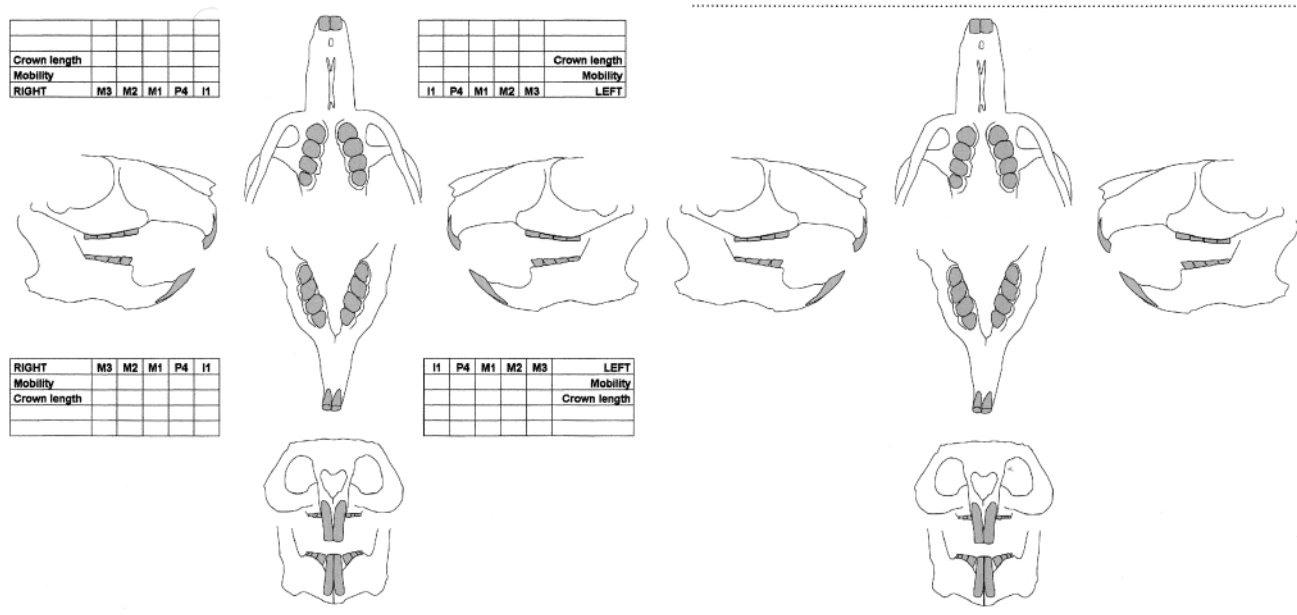


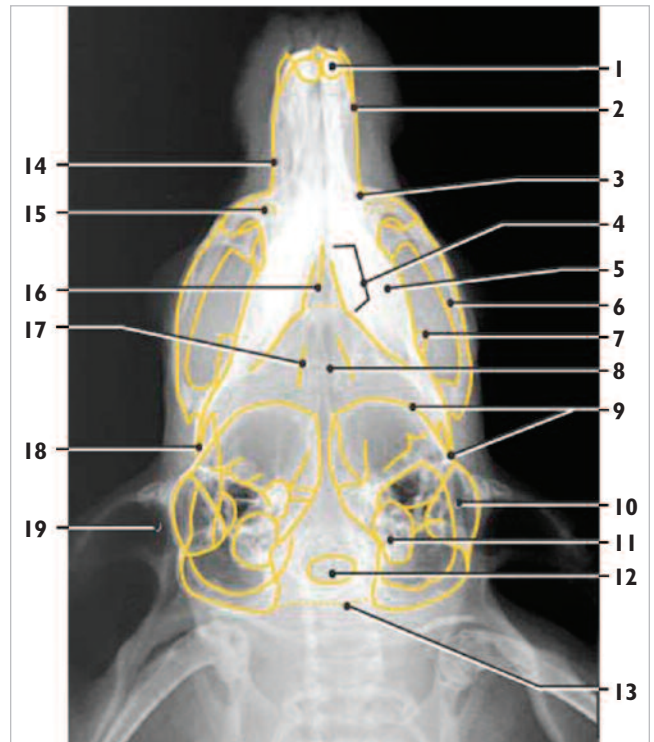
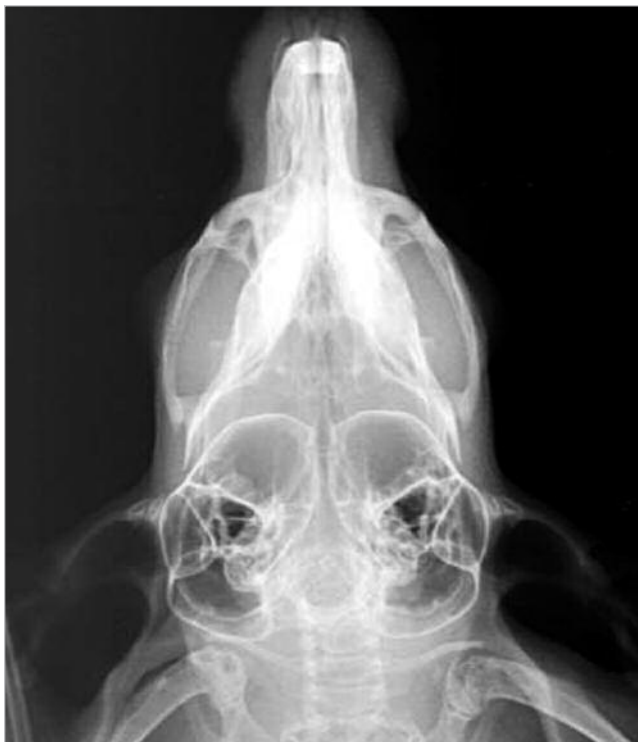Figure 5. Dental charts that we use to record oral examination findings and the procedures performed.

to 45° angle to provide optimal intraoral visualization. These restraint devices can be useful to individual practitioners when technical assistance is limited or unavailable; however, they may cause trauma if improperly used. Potential complications associated with the use of these restraint devices include overextension of the neck and spine, compression of the larynx due to excessive retraction, and difficulty maneuvering dental instruments around the device. If great care is taken to ensure appropriate positioning of the patient and the practitioner can maneuver around the device while performing dental corrections, these devices can be quite useful.

The intraoral examination should be performed systematically, inspecting one quadrant at a time and each tooth individually. A dental explorer should be used to

assess tooth mobility and integrity. Periodontal probes are too large and should not be used in a chinchilla's small oral cavity; a right-angled explorer can be used instead. A normal oral examination should demonstrate a flat and correctly angled occlusal surface, with the premolars and molars visible just above the gingival margin (1 mm). There should be no points or prominences associated with the occlusal surface of the premolars and molars, and no periodontal pockets should be identified. The incisors should be pigmented orange yellow (as in most other rodents) on the facial aspect of the tooth and properly aligned. It is very useful to document or chart the mouth of a chinchilla in the same fashion as is done for dogs and cats (Figure 5). Charting can be extremely useful when performing frequent occlusal corrections to track treatment progress.

Figure 6. Conventional dorsoventral radiograph of a normal adult chinchilla skull. (Reprinted with permission from Silverman S, Tell LA: *Radiology of Rodents, Rabbits, and Ferrets*. St. Louis, Elsevier, 2005)

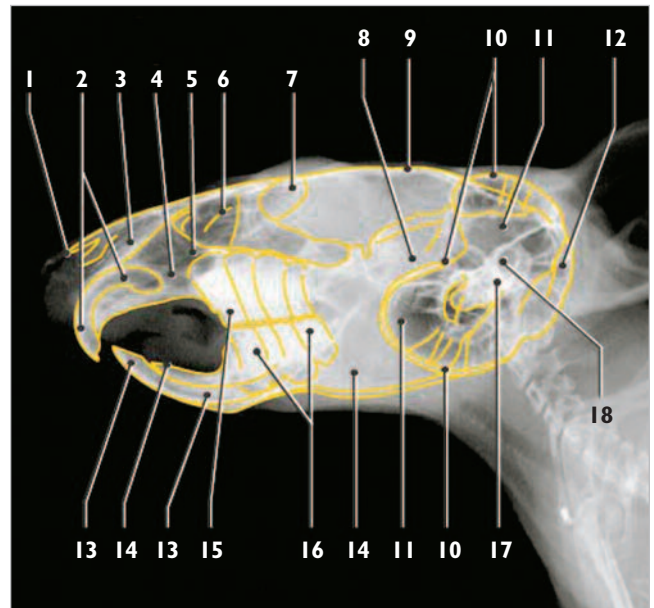
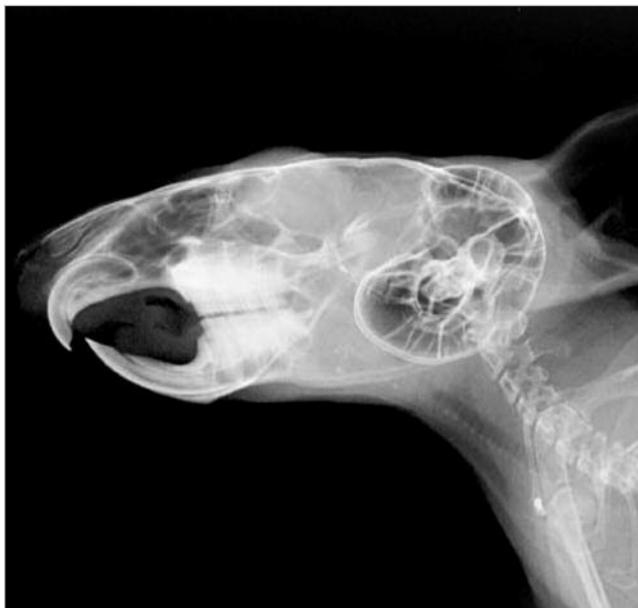

Unlabeled view.

1—Maxillary incisor, 2—Incisive bone, 3—Zygomatic process of maxilla, 4—Premolar and molar teeth, 5—Mandible, 6—Zygomatic bone, 7—Coronoid process of the mandible, 8—Basisphenoidal bone, 9—Tympanic bulla, 10—Tympanic cavity, 11—Petrous part of the temporal bone, 12—Foramen magnum, 13—Occipital bone, 14—Maxilla, 15—Infraorbital hiatus, 16—Vomer, 17—Pterygoid bone, 18—Angular process of the mandible, 19—Ear canal

Labeled view.

Figure 7. Conventional right lateral radiograph of a normal adult chinchilla skull. (Reprinted with permission from Silverman S, Tell LA: *Radiology of Rodents, Rabbits, and Ferrets*. St. Louis, Elsevier, 2005)

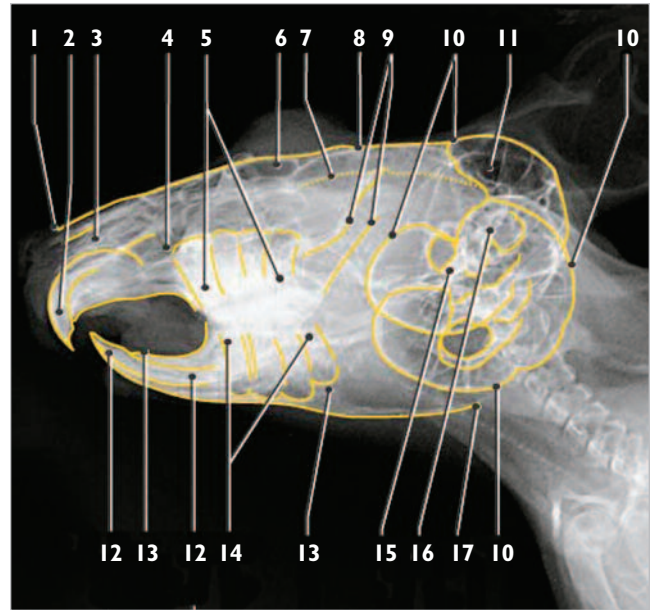
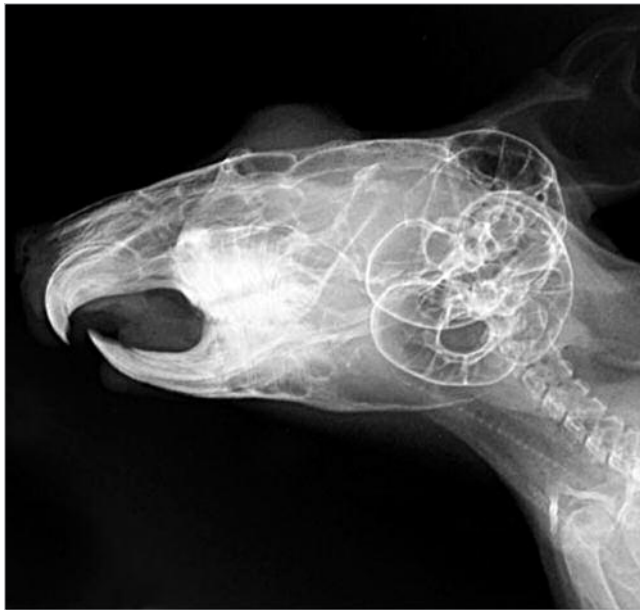

Unlabeled view.

1—Nasal bone, 2—Maxillary incisor tooth, 3—Incisive bone, 4—Maxilla, 5—Nasal cavity, 6—Ethmoturbinates, 7—Frontal bone, 8—Temporal bone, 9—Parietal bone, 10—Tympanic bulla(e), 11—Tympanic cavity, 12—Occipital bone, 13—Mandibular incisor tooth, 14—Mandible, 15—Maxillary premolar tooth, 16—Mandibular premolar and molar teeth, 17—Petrous part of the temporal bone, 18—External acoustic meatus

Labeled view.

Figure 8. Conventional right oblique radiograph of a normal adult chinchilla skull. (Reprinted with permission from Silverman S, Tell LA: *Radiology of Rodents, Rabbits, and Ferrets*. St. Louis, Elsevier, 2005)

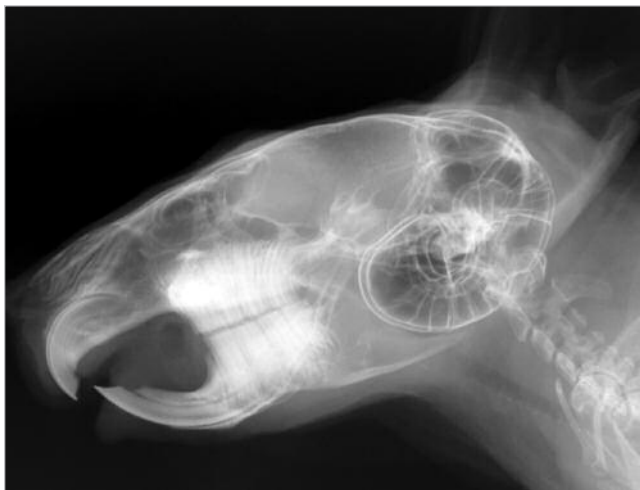

Unlabeled view.

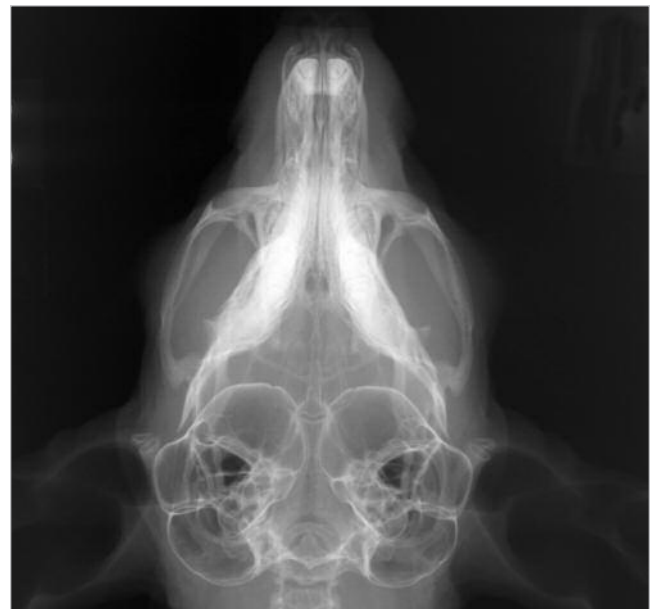Labeled view.

- 1—Nasal bone, 2—Maxillary incisor tooth, 3—Incisive bone, 4—Maxilla, 5—Maxillary premolar and molar teeth, 6—Frontal bone, 7—Zygomatic bone, 8—Parietal bone, 9—Coronoid process of the mandible, 10—Tympanic bulla, 11—Tympanic cavity, 12—Mandibular incisor tooth, 13—Mandible, 14—Mandibular premolar and molar teeth, 15—Petrus part of the temporal bone, 16—External acoustic meatus, 17—Angular process of the mandible

Figure 9. Radiographs of an adult chinchilla with mild dental disease. These radiographs demonstrate proper occlusion, but the reserve crowns are apically elongated into the maxilla and mandible, the maxillary apices are protruding several millimeters past the line from the base of the incisors to the tympanic bullae, and the mandibular apices are deforming the ventral margin of the mandible.

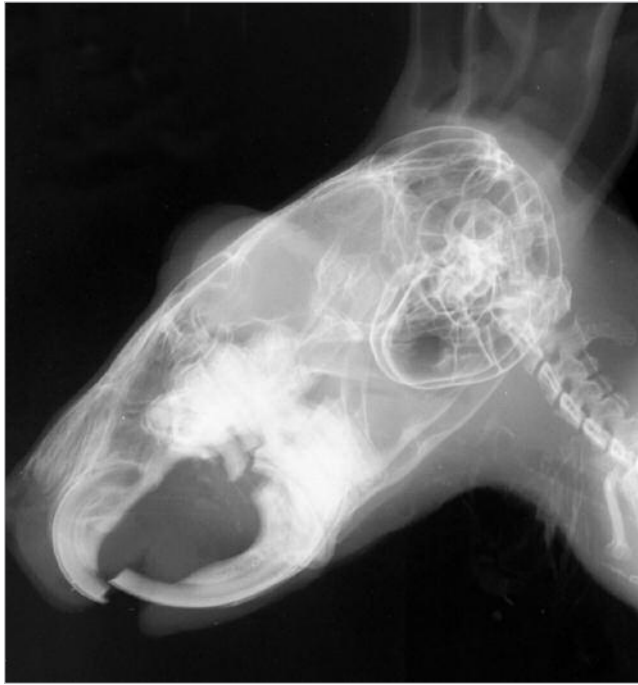

Lateral view.

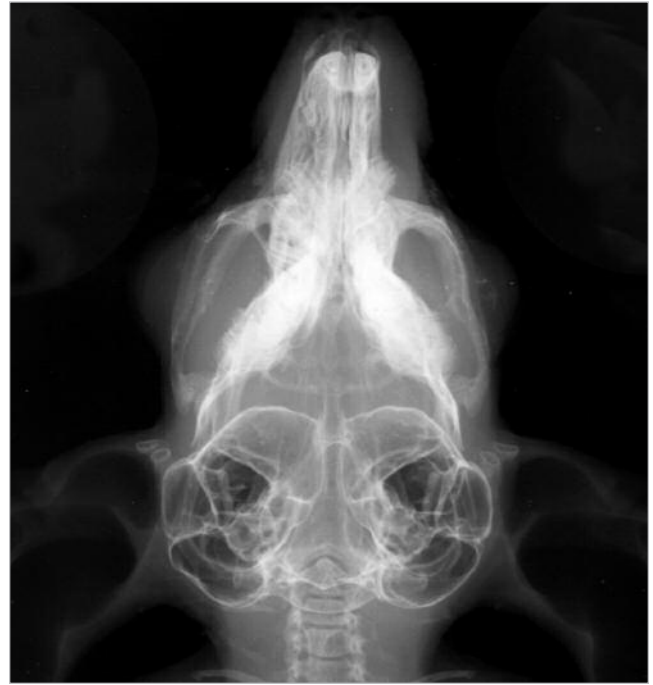

Dorsoventral view.

Figure 10. Radiographs of an adult chinchilla with severe premolar–molar malocclusion, periodontal and endodontic disease, and moderate incisor malocclusion. Premolar and molar root elongation and deformation of the ventral margin of the mandibles are also evident in both views.



Lateral view.



Dorsoventral view.

Conventional Radiography

Radiography of the chinchilla head should be performed with the patient under general anesthesia. Ideally, high-contrast, high-resolution radiographs should be obtained with minimal variation in patient positioning. The minimal standard conventional projections for radiographs of a chinchilla head should include dorsoventral and right lateral views. However, five views, including dorsoventral, right and left lateral, and right and left oblique projections, are ideal (Figures 6, 7, and 8). Radiography can be used to distinguish chinchillas with normal dentition (Figures 6, 7, and 8) from those with mild (Figure 9) or severe (Figure 10) dental disease.

graphic abnormalities. Magnification radiography uses the same projections as conventional radiography. The principles of magnification radiography have been previously described.¹⁸ The major advantage of magnification radiography is enhancement of radiographic abnormalities via image enlargement. The major disadvantage of magnification radiography is loss of image sharpness.

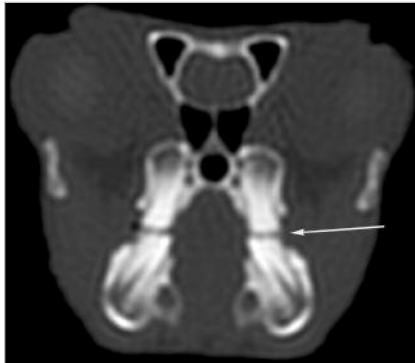
Computed Tomography

Because of the increased sensitivity of computed tomography (CT) in detecting subtle skeletal or bony changes in patients with thin cortices (e.g., chinchillas), CT is the most valuable diagnostic imaging tool for

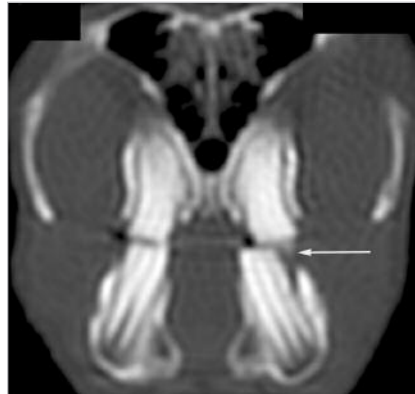
Gross dental disease may not be evident in chinchillas.

Because of the small size of the chinchilla head, magnification radiography on single emulsion radiographic film may be an important addition to standard dorsoventral and lateral radiographic projections. This type of imaging enhances the viewer's ability to detect radio-

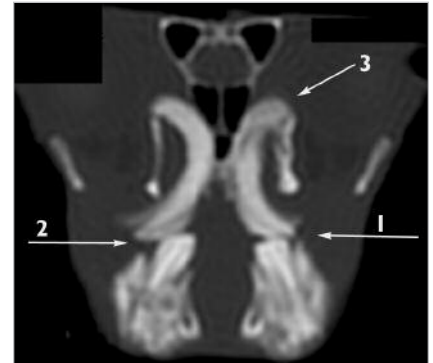
detecting early premolar and molar abnormalities⁵ (Figure 11). CT may also provide more detail in evaluating soft tissue changes (e.g., in the nasal cavity) compared with conventional radiography and is also a more sensitive technique in evaluating the tympanic bullae and the

Figure 11. Transverse CT images of an adult chinchilla skull.

Normal dentition (1-mm slice). The arrow denotes the proper occlusal surface and alignment of the cheek teeth.



Mild dental disease (1-mm slice). The maxillary reserve crowns have begun to penetrate the alveolar bone into the infraorbital region. The arrow denotes the buccal point on the right maxillary molar and malalignment of the maxillary and mandibular molars' occlusal surface.



Severe dental disease (2-mm slice). Arrows 1 and 2 denote the increased angulation of the molars as well as buccal maxillary and lingual mandibular points. The mandibular reserve crowns have penetrated beyond their normal margins, and the reserves show abnormal curvature. The maxillary reserve crowns have penetrated and destroyed the alveolar bone extending into the orbits (arrow 3).

temporomandibular joints. One-millimeter axial slices initiated at the most cranial aspect of the rostrum, with the chinchilla in sternal recumbency, are optimal because of the small size of chinchillas. The disadvantages of CT are limited availability and higher cost compared with conventional radiography.

CONCLUSION

Dental disease is one of the most common reasons for presentation of chinchillas to a veterinarian. Therefore, it is important to understand the normal anatomy and dentition of chinchillas to accurately diagnose dental disease. Diagnostic imaging must be part of the minimum database to establish a diagnosis of dental disease, better evaluate the severity of the disease, and develop an appropriate treatment plan. It is equally important that clinicians encourage annual or biannual oral examinations for their chinchilla patients and educate caretakers regarding proper husbandry of chinchillas as a preventative to dental disease.

REFERENCES

1. Popesko P, Rajtova V, Horak J: *A Colour Atlas of Anatomy of Small Laboratory Animals*, vol 1. Philadelphia, WB Saunders, 1992.
2. Verstraete FJM: Advances in diagnosis and treatment of small exotic mammal dental disease. *Semin Avian Exot Pet Med* 12(1):37–48, 2003.
3. Crossley DA: Dental disease in chinchillas in the UK. *J Small Anim Pract* 42:12–19, 2001.
4. Crossley DA, Miquelez MM: Skull size and cheek-tooth length in wild-caught and captive bred chinchillas. *Arch Oral Biol* 46:919–928, 2001.
5. Crossley DA, Jackson A, Yates J, Boydell IP: Use of computed tomography to investigate cheek tooth abnormalities in chinchillas (*Chinchilla lanigera*). *J Small Anim Pract* 39:385–389, 1998.
6. Crossley DA: Clinical aspects of rodent anatomy. *J Vet Dent* 12(4):131–135, 1995.
7. Crossley DA, Dubielzig RR, Benson KG: Caries and odontoclastic resorptive lesions in a chinchilla (*Chinchilla lanigera*). *Vet Rec* 141:337–339, 1997.
8. Silverman S, Tell LA: *Radiology of Rodents, Rabbits, and Ferrets*. St. Louis, Elsevier, 2005, pp 68–104.
9. *Nomina Anatomica Veterinaria*, ed 4. Zurich and Ithaca, World Association of Veterinary Anatomists, 1994.
10. Evans HE: The skull, in Evans HE (ed): *Miller's Anatomy of the Dog*, ed 3. Philadelphia, WB Saunders, 1993, pp 128–166.
11. Hildebrand M: *Analysis of Vertebrate Structure*, ed 4. New York, John Wiley & Sons, 1995.
12. Myers P: Chinchillidae. University of Michigan, Museum of Zoology. Accessed September 2005 at <http://animaldiversity.ummz.umich.edu/chordata/mammalian/rodentia/chinchillidae.html>.
13. Kraft H: *Disease of Chinchillas*. Neptune, NJ, TFH Publications, 1987, pp 116–120.
14. Medow H: *The Chinchilla*. Redwood City, CA, The Tozer Co, 1969, pp 60–70.
15. Houston JW: *Chinchilla Care*. Gardena, CA, Allied Fur Industries, 1951, pp 46–60.
16. Bickel E: *Chinchilla Handbook*. Neptune, NJ, TFH Publications, 1987, pp 95–127.
17. Mazuri: Chinchilla feed analysis. Grey Summit, MO, PMI Nutrition International, LLC.
18. Tell LA, Silverman S, Wisner E: Imaging techniques for evaluating the head of birds, reptiles and small exotic mammals. *Exotic DVM* 5(2):31–37, 2003.

ARTICLE #3 CE TEST



This article qualifies for 2 contact hours of continuing education credit from the Auburn University College of Veterinary Medicine. Subscribers may purchase individual CE tests or sign up for our annual CE program. Those who wish to apply this credit to fulfill state relicensure requirements should consult their respective state authorities regarding the applicability of this program. To participate, fill out the test form inserted at the end of this issue or take CE tests online and get real-time scores at CompendiumVet.com.

1. Which is a common clinical presentation of dental disease in chinchillas?

- a. fur chewing
- b. head tilt
- c. ptyalism (“slobbers”)
- d. ocular discharge
- e. c and d

2. Major anatomic differences in chinchillas compared with other rodents include

- a. large infraorbital foramina, large tympanic bullae, and lacrimal canals that open to the side of the rostrum.
- b. small tympanic bullae and no infraorbital foramina.
- c. a large masseteric crest and prominent zygomatic arches.
- d. b and c
- e. none of the above

3. Because chinchillas have long crowns with no anatomic roots, the correct term for the cheek teeth roots is

- a. roots.
- b. open-rooted.
- c. reserve crown.
- d. crown.
- e. a and b

4. The most thorough way to visualize the oral cavity of a chinchilla during an intraoral examination is with an

- a. awake patient and no instrumentation.
- b. awake patient and a speculum attached to an otoscope.
- c. awake patient and a cheek pouch dilator.
- d. awake patient and a cheek pouch dilator and speculum.
- e. anesthetized patient and a cheek pouch dilator and speculum.

**Test answers now available at
CompendiumVet.com**

5. The color of a chinchilla's incisors should

- a. be similar to that of rabbit incisors (i.e., white).
- b. be orange yellow around the entire tooth.
- c. be orange yellow on the facial aspect of the tooth, as in most other rodents.
- d. vary, depending on age.
- e. vary, depending on diet.

6. The most desirable imaging technique or combination to consider when taking conventional radiographs of a chinchilla head is

- a. low contrast with high resolution.
- b. high contrast with low resolution.
- c. low contrast with low resolution.
- d. high contrast with high resolution.
- e. none of the above

7. The two main radiographic projections of a chinchilla skull that should always be evaluated are

- a. lateral and ventrodorsal.
- b. oblique and ventrodorsal.
- c. lateral and dorsoventral.
- d. oblique and lateral.
- e. right and left lateral.

8. The most sensitive tool for diagnosing early dental disease in chinchillas is

- a. palpation of the mandibles.
- b. conventional skull radiography.
- c. oral examination of awake patients.
- d. CT.
- e. assessment of clinical signs.

9. Which is an important factor(s) to consider when treating chinchillas with dental disease?

- a. Dietary roughage should include timothy, grass, or oat hays and fresh vegetables and greens.
- b. Food pellets should be no less than 16% to 20% crude fiber.
- c. Clients should be discouraged from breeding affected chinchillas.
- d. Frequent dental evaluations and corrective therapy may be required for the life of affected chinchillas.
- e. all of the above

10. Documenting or charting the dentition of chinchillas with dental disease is important for

- a. recording dental corrections.
- b. recording occlusal abnormalities.
- c. tracking patient progress.
- d. a and b
- e. all of the above