Article #1

The Canine Meniscus: Injury and Treatment

Karyn K. Briggs, DVM, MS
The Center for Specialized Veterinary Care
Westbury, New York

ABSTRACT:

Meniscal tears are a common clinical finding in dogs. Injuries usually involve the medial meniscus and typically occur following cranial cruciate rupture. Treatment options include primary repair, total meniscectomy, partial meniscectomy, and hemimeniscectomy. The treatment of choice for meniscal tears is primary repair or partial meniscectomy, if possible, at the time of stifle stabilization. Meniscectomy inevitably leads to osteoarthritis and a perpetual cycle of articular cartilage degeneration. Ongoing research is focused on increasing the healing potential of the meniscus via improved blood supply and matrix scaffolds. In cases of severe damage, meniscal transplants or prostheses may be available in the future.

Meniscal injuries are common in cranial cruciate–deficient stifles. This article reviews the anatomy, function, pathophysiology of injury, diagnosis, treatment, and areas of current research pertaining to meniscal disease.

ANATOMY

The medial and lateral canine menisci are C-shaped, fibrocartilaginous disks found in the stifle between the articulating surfaces of the femur and tibia. The menisci are anchored to the tibia and femur by five meniscal ligaments and to each other by a single intermeniscal ligament. The five meniscal ligaments are the cranial tibial ligaments of the lateral and medial meniscus, caudal tibial ligaments of the lateral and medial meniscus, and femoral ligament of the lateral meniscus (Figure 1). In addition to the ligamentous attachments, the medial meniscus is firmly attached to both the joint capsule and the medial collateral ligament. These additional attachments make the medial meniscus less mobile than the lateral meniscus. The lateral meniscus is not attached to the lateral collateral ligament and has fewer attachments to the joint capsule, particularly around the popliteal tendon.[1,2]

Menisci are composed of dense fibrocartilage containing collagen (type I),[a] proteoglycans, elastin, and chondrocytes.[1,2] The meniscal horns are richly innervated with mechanoreceptors and free nerve endings compared with the meniscal body.[3] The body of the meniscus has minimal blood supply, whereas the meniscal horns have an abundant blood supply. A vascular plexus within the joint capsule derived from the medial and lateral genicular arteries supplies only the peripheral 25% of the meniscus.[4] The remainder of the meniscal body relies on diffu-

[a]The difference between types I and II collagen has to do with the amino acid composition of the alpha chains. Type I has two identical alpha chains as well as a third alpha chain with a different amino acid composition. Type I also has a low content of hydroxylysine and glycosylated residues compared with type II, which has three identical alpha chains.

Email comments/questions to **compendium@medimedia.com**, fax **800-556-3288**, or log on to **www.VetLearn.com**

Figure 1. Menisci and surrounding anatomy.

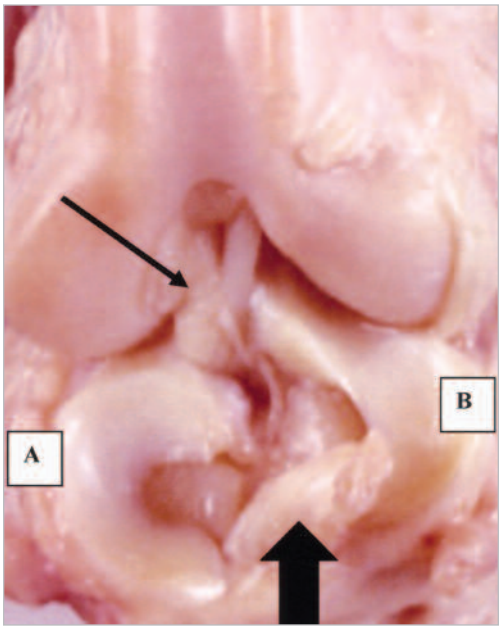

Dissected stifle held in a cranial drawer position exposing the medial meniscus *(A)*, lateral meniscus (*B*), transected cranial cruciate ligament *(thick arrow)*, and caudal cruciate ligament *(thin arrow)*.

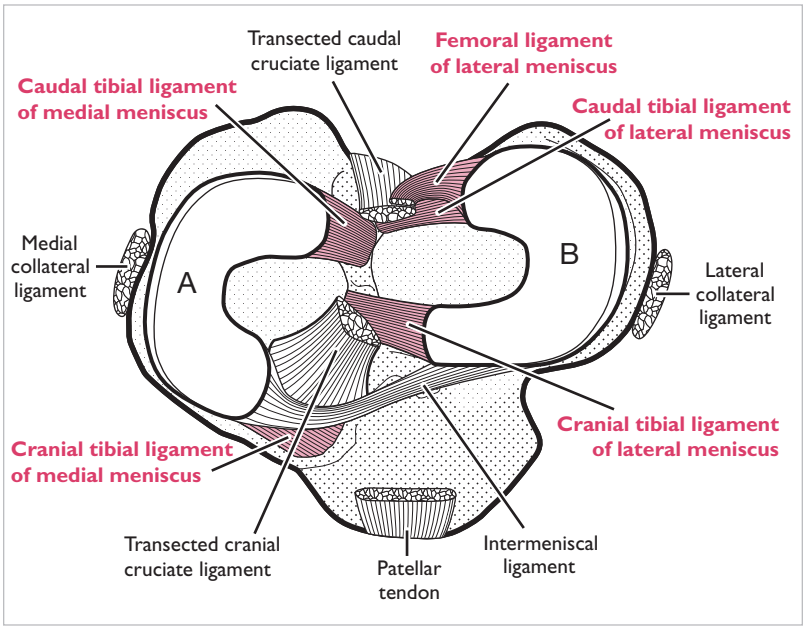

Tibial plateau and menisci.

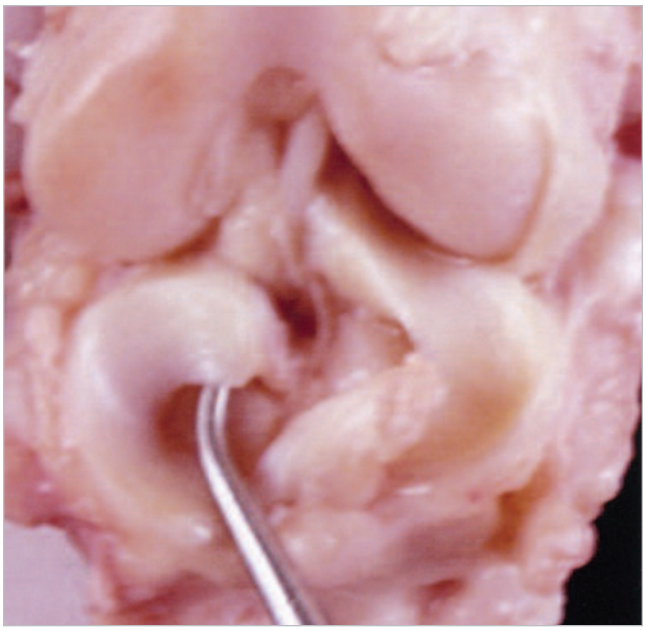

Caudal tibial ligament of the medial meniscus (the probe is beneath it).

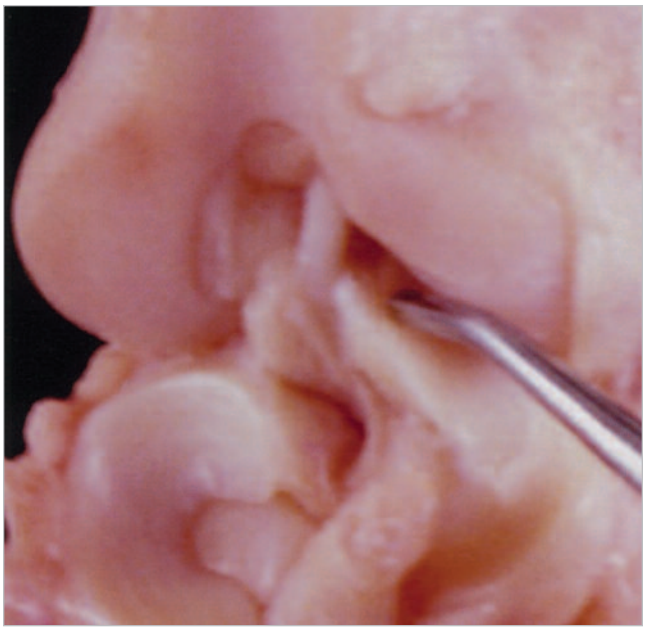

Femoral ligament of the lateral meniscus (the probe is pointing to it).

sion of synovial fluid for nourishment. Because of this sparse blood supply, meniscal injuries occurring axial to the peripheral rim rarely heal and thus have great clinical significance.

FUNCTION

The menisci serve many functions within the stifle joint. They perform a load-transmitting function by distributing approximately 65% of the compressive load

Figure 2. Meniscal tears.

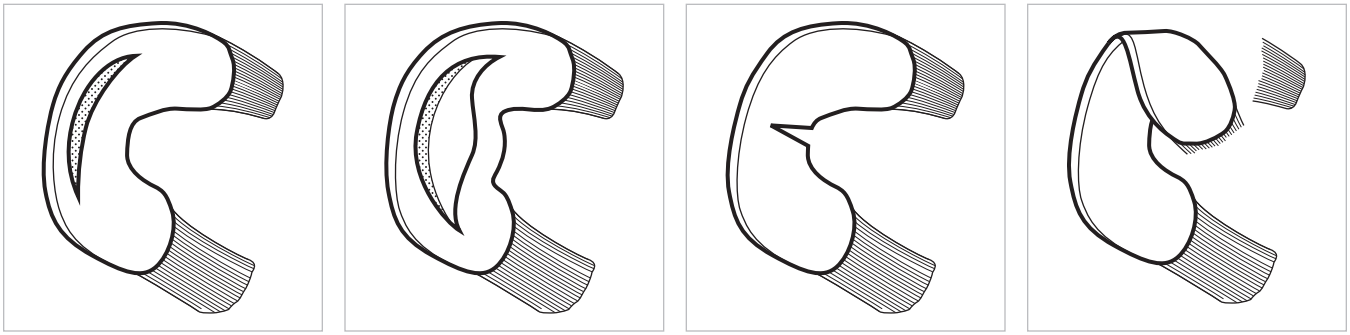

Longitudinal tear. Bucket-handle tear. Transverse tear. Folded caudal pole.

delivered during weight bearing.[1,4] By distributing this compressive force, the menisci spare the articular cartilages of the femur and tibia. This load-distributing function is made possible by the five meniscal ligaments. Axial joint loading tensions these insertional ligaments and the circumferential collagen fibers of the meniscal body. As a result, a portion of the compressive load is transformed into hoop stresses[b] at the meniscal periphery, thus sparing the articular cartilage.[3] The flexible menisci also improve joint stability by improving incongruity between the femur and tibia.[2] The nerve supply to the menisci is thought to provide a sensory function, allowing precise muscle actions to occur in response to pressure changes in the joint.[2] They are also thought to contribute to the hydrostatic lubrication of articular cartilage and prevent synovial entrapment between weight-bearing surfaces.[1,4]

INJURY

In dogs, meniscal injury is almost always associated with rupture, either partial or complete, of the cranial cruciate ligament. When meniscal injury is associated with acute or chronic cruciate disease, the medial meniscus is damaged in 96% to 100% of cases.[2,4,5] This correlation is directly attributed to the anatomic difference between the two menisci. The medial meniscus is more firmly attached to the tibia, joint capsule, and medial collateral ligament than the more mobile lateral meniscus. Therefore, when the cranial cruciate ligament fails, the cranial displacement of the tibia, when weight bearing, wedges the medial meniscus between the femoral condyle and the tibial plateau. Excessive internal rotation of the tibia during stifle flexion following cruciate rupture may also contribute to medial meniscal damage from the medial femoral condyle as part of the "screw home" mechanism.[c,5] The lateral meniscus is spared this fate because of the presence of the caudal femoral attachment, which allows increased mobility.[1] However, several reports have identified lateral meniscal injuries, including a recent publication describing radial tears in the cranial horn of the lateral meniscus in 77% of cranial cruciate deficient stifles undergoing arthroscopy.[6,7] Although Hulse and Johnson[7] described lameness associated with a lateral caudal pole tear, the clinical significance of most lateral meniscal tears is unknown.

When associated with cranial cruciate rupture, injury to the medial meniscus may occur during the rupture or as a function of chronic joint instability.[8] Forty-eight percent to 70% of patients presented for cranial cruciate rupture have concurrent medial meniscus damage.[2,8,9] The damage to the medial meniscus can be classified based on anatomic orientation and the type of tear (Figure 2). Different lesions reported include a folded caudal horn, longitudinal tears, fibrillation of the surface, transverse tears, "bucket-handle" tears, and compression injuries.[2,8] The bucket-handle tear and folded caudal horn (pole) are the most commonly reported medial meniscal tears.[2,9]

Although most meniscal injuries in dogs result from cranial cruciate ruptures, other reported abnormalities

[b]*Hoop stresses* refers to tensioning of circumferential fibers and ligamentous attachments of the meniscus under load-bearing situations that transmits the load through the meniscus itself and away from the articular cartilage of the tibia and femur.

[c]*Screw home mechanism* is a term used in human medicine to describe excessive internal rotation of the tibia during stifle flexion following cruciate failure. The tibia then externally rotates during stifle extension. The significance is that this excessive internal rotation, along with the anatomic differences between the medial and lateral menisci, may play a role in predisposing the medial meniscus to damage by the medial femoral condyle.

include meniscal calcification and ossification, lateral meniscal damage secondary to osteochondritis dissecans lesions,[10] and meniscal injuries secondary to multiple ligamentous injuries from automobile trauma (deranged stifles). Clinical signs of meniscal injuries without concurrent cruciate tears include mild to severe hindlimb lameness, joint effusion, pain on flexion and extension of the stifle, and an audible meniscal click. Meniscal ossification (formation of bone within meniscal tissue) and mineralization (deposition of minerals, mainly calcium) may be primary or secondary conditions. The primary form is considered idiopathic, and the presence of ossicles (small pieces of bone that form within soft tissues) is considered normal in reptiles, amphibians, birds, and some rodents. In higher mammals, they are rare but may be vestigial structures.[10] Ossification or mineralization may also occur secondary to either metabolic abnormalities or trauma such as cranial cruciate rupture. Metabolic abnormalities include pseudogout in dogs and hyperparathyroidism and hypothyroidism in humans.[10,11]

Although cranial cruciate tears have traditionally been thought to occur in large-breed dogs, small breeds and cats can also be affected. Any animal with a cranial cruciate tear is at risk of a meniscal injury. An in-depth discussion on cruciate disease is beyond the scope of this article.

DIAGNOSIS

Physical examination and historic findings can lend suspicion to meniscal injury, but definitive diagnosis is typically made during surgery with either arthroscopy or arthrotomy. Clients may report an audible "clicking" sound when the patient ambulates, or a click may be producible on flexion and extension of the stifle, often indicating meniscal damage. A lack of a meniscal click does not rule out the presence of meniscal pathology. Patients may also have acute exacerbation of lameness when a meniscal injury occurs. Eliciting a cranial drawer sign may be hindered if a folded or torn caudal pole is wedged between the femoral condyle and the tibia, thus fixing the tibia in a cranial drawer position.

Other modalities that have been used to identify meniscal disease noninvasively in humans include ultrasonography and magnetic resonance imaging (MRI). In humans, the posterior half of the medial meniscus can be visualized consistently using ultrasonography, whereas the posterior half of the lateral meniscus is inconsistently seen. In dogs, neither caudal pole can reportedly be visualized.[12,13] However, one study used ultrasonography when evaluating meniscal regeneration in the caudal pole of the medial meniscus.[14] MRI is a common modality used in humans to diagnose stifle abnormalities, including meniscal tears, ligamentous injuries, and cartilage lesions. When using fat-saturated T_2-weighted or proton density–weighted sequences, the sensitivity of diagnosing radial meniscal tears was 89% as confirmed by arthroscopy; the other 11% was false-negative findings.[15] Other reports have published sensitivities and specificities for meniscal tears ranging from 90% to 95%.[16] Normal canine stifle structures have been described with low-field MRI, but it is seldom used for diagnosing meniscal injury in veterinary medicine.[17]

Current research is focusing on increasing the healing potential of the largely avascular meniscus.

TREATMENT

Because of lack of adequate blood supply to the meniscus and poor healing potential, surgery is the treatment of choice for meniscal injuries. Visualization is paramount in evaluating the integrity of the menisci and initiating definitive treatment. This can be accomplished with a medial or lateral parapatellar arthrotomy or arthroscopy. To view the menisci with a parapatellar arthrotomy, the tibial plateau should be levered cranially with a Hohmann retractor or mosquito hemostat placed at the caudal aspect of the plateau or hooked under the intermeniscal ligament. By placing the tibial plateau in a cranial drawer position and using suction to remove excess joint fluid, the menisci can be fully viewed and probed for tears. Stifle retractors are also available to help improve visualization of the menisci. Arthroscopy can also be performed to visualize the components of the joint, debride remaining cruciate fibers, and address meniscal tears. The caudal pole of the medial meniscus can also be accessed through arthrotomy just caudal to the medial collateral ligament. This alternative approach is very limited and does not allow visualization of the

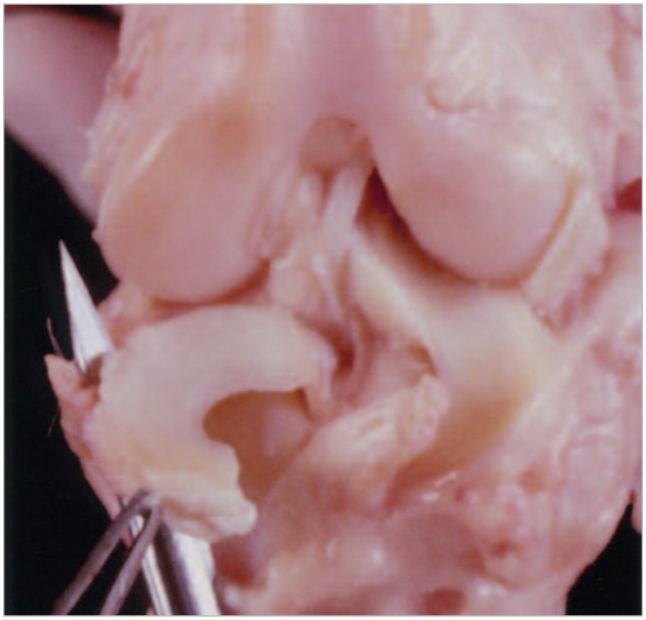

Figure 3. Total medial meniscectomy starting at the cranial pole.

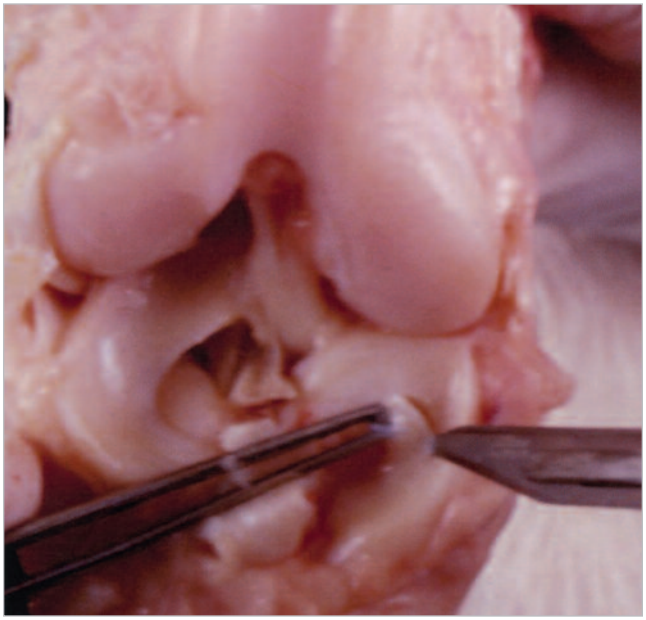

Figure 4. Partial meniscectomy. Only the damaged portion of the meniscus is resected, leaving the healthy outer rim.

cranial cruciate ligament. However, caudal pole meniscal tear procedures and meniscal releases can be performed with this technique, which is most commonly used during tibial plateau leveling osteotomy (TPLO).

Treatment options for damaged menisci include total meniscectomy (removing the entire meniscus), partial meniscectomy (removing only the damaged portion), hemimeniscectomy (removing the entire caudal pole), or primary repair. Proponents of total meniscectomy contend that it eliminates potential for continued clinical lameness due to lesions left behind from a partial meniscectomy and is technically easier to perform than some other techniques[8] (Figure 3). Total meniscectomy also allows partial regeneration by fibrocartilaginous material from the well-vascularized joint capsule.[18] However, this regenerate material likely cannot distribute load by creating hoop stresses. Twenty-eight experimental canine total meniscectomies performed by Flo[8] had regenerative fibrocartilage. However, articular cartilage changes, including softening and fibrillation, were noted 12 months after surgery.

Nevertheless, partial meniscectomy has become the technique of choice for many surgeons because it has been shown to result in fewer degenerative changes than does total meniscectomy[4,19,20] (Figure 4). Partial meniscectomy also allows a portion of the meniscus to remain in situ and provide lubrication and protection to the articular cartilage.[1] Malcolm and Daniel[21] evaluated the change in pressure transmitted to the articular cartilage following removal of portions of the lateral meniscus and documented that an intact meniscus transmits 29% of the load. When one-quarter of the meniscus is removed, the load transmitted increases to 45%; when a total meniscectomy is performed, the load transmitted increases to 313%. The conclusion was that the peripheral rim of meniscus remaining intact following a partial meniscectomy provides protective effects for the articular cartilage and decreased degenerative change.[21] Data for changes in load transmission following partial meniscectomy of the medial meniscus were not described.

Because of its unique anatomy, the medial meniscus is preferentially damaged in cranial cruciate–deficient stifles.

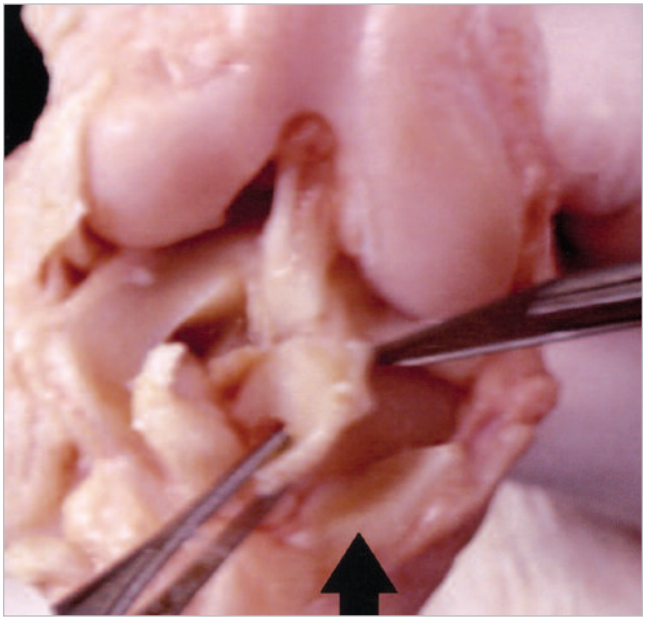

Figure 5. Hemimeniscectomy. Only the caudal pole is resected, leaving the healthy cranial pole *(arrow)*.

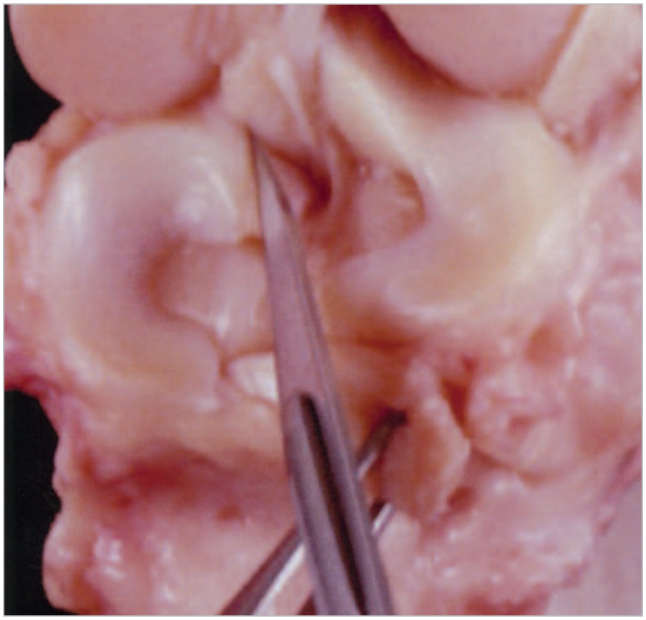

Figure 6. Medial meniscal release at the caudal tibial attachment.

Hemimeniscectomy is removal of the caudal pole of the meniscus while the cranial pole remains intact (Figure 5). This procedure may be indicated when there is extensive injury to and fibrillation of the caudal pole, preventing the surgeon from sparing a normal rim of meniscus with a partial meniscectomy. However, hemimeniscectomy has been shown to have no advantages over total meniscectomy in terms of degenerative changes noted, despite the caudal pole being replaced by fibrocartilage.[22–24]

Primary repair involves direct suturing of the torn meniscus or suturing the meniscus to its peripheral joint capsule attachments. This technique has the advantage of leaving the meniscus in situ, thus providing continued protection of the articular cartilage. Disadvantages include technical difficulty and potential for poor healing, given the lack of adequate blood supply to 75% of the axial region. Historically, primary repair was performed only in cases of peripheral capsular tears.[1] However, a recent report has documented primary repair in 92 meniscal injuries—either caudal peripheral detachment from the joint capsule or full-thickness longitudinal tears in the abaxial periphery—with good results.[25] Despite this encouraging report, primary repair of the meniscus is not commonly performed in veterinary medicine.

A meniscal release involves either a mid-body medial meniscus transection or transection of the caudal tibial ligament (Figure 6). These maneuvers are intended to allow the caudal horn more mobility in the presence of cranial tibial thrust.[26] The maneuver is part of TPLO for cranial cruciate repair. Either method of release can be performed through a parapatellar arthrotomy. The mid-body transection can also be performed through a small arthrotomy caudal to the medial collateral ligament. In a clinical evaluation of 212 stifles over 4 years, no cases of injury to the medial meniscus were noted following meniscal release in conjunction with TPLO.[26] Another study evaluated the effects of medial meniscal releases in rabbits via transection of either the cranial or caudal tibial ligament. Histologic evaluation at 6 and 12 weeks after surgery revealed healing of the ligaments in elongated positions, increased articular cartilage degeneration at the medial tibial plateau, and synovitis within the treated joints.[27] Transecting the medial meniscus at either the tibial ligament or mid-body would theoretically eliminate formation of hoop stresses during axial loading and decrease load distribution. However, given the promising clinical results for preventing meniscal injury after cruciate rupture, further studies are warranted to define the effects of meniscal release in dogs.

Because meniscal injuries are nearly always associated with cranial cruciate rupture and the progression of osteoarthritis, pain management is an important aspect of treatment. In the perioperative period, pain can be

addressed with a combination of local anesthetics such as epidural or intraarticular bupivacaine, epidural or systemic opioids, and NSAIDs. For chronic lameness associated with osteoarthritis, management is multimodal, including weight loss for obese animals. Consistent low-impact exercise modification and physical therapy along with oral disease-modifying osteoarthritic drugs (e.g., glucosamine, chondroitin sulfate) can be combined with weight management to minimize the necessity of daily NSAID use. Readers should review more comprehensive publications on long-term management of osteoarthritis.

CURRENT RESEARCH

Because of the inevitable progression of osteoarthritis following meniscectomy (partial, total, or hemimeniscectomy), research has focused on improving the healing potential of the meniscus via improved blood supply and matrix scaffolds. Hulse et al[28] investigated the use of vascular access channels or incisions made through remaining meniscal tissue to the peripheral synovium after partial meniscectomy. This exposes the nonvascular axial portion of the meniscus to the blood supply from the synovial vascular plexus and promotes healing and regeneration. Other methods include using free synovium or synovial pedicle flaps.[29,30] A recent attempt to increase vascular supply involved using bioengineered meniscal tissue from cows treated with an adenovirus vector encoding the hepatocyte growth factor gene to induce blood vessel formation.[31]

Matrix biomaterials can also be used as a scaffold for meniscal regeneration with varying success. Some examples include using fibrin clots, porcine small intestinal submucosa, and collagen implants.[14,32–35] Welch et al[33] investigated placing small intestinal submucosa in 4-mm defects in an avascular portion of the medial meniscus in 16 dogs. Fifty percent of the defects were filled with small intestinal submucosa, and 50% served as controls. Healing was compared between the two groups, and no increased tissue regeneration was noted in the dogs with small intestinal submucosa implants.[33] However, Cook et al[14] demonstrated meniscal regeneration in four of five dogs that received small intestinal submucosa implants in surgically created meniscal defects (caudal pole hemimeniscectomy) compared with control dogs. Because hemimeniscectomy involves both the vascular and avascular portion of the meniscus, access to a blood supply may explain the more positive results from the study by Cook et al.[14] Encouraging results have also been reported with collagen implants formulated from type I collagen from bovine Achilles tendons. In a phase 2 clinical study, eight humans received these meniscal implants and were followed for at least 24 months. All eight patients improved clinically based on pain and activity scores and had no progression of osteoarthritis.[36]

Another avenue of research has sought to replace severely damaged menisci with either biologic transplants (autogenous or allogenic) or permanent prostheses. Autogenous sources of tissue have included the quadriceps and Achilles tendons.[37,38] Allogenic implants from cadaveric sources have been shown to heal to the joint capsule following transplantation in approximately 80% of cases, and promising short-term clinical improvements have been well documented.[39–41] Attempts have also been made to develop an artificial meniscal prosthesis. Although numerous materials have been tested, a recent study using polyvinyl alcohol hydrogel in rabbits yielded promising results.[42]

Partial meniscectomy is associated with fewer degenerative changes compared with total meniscectomy and hemimeniscectomy.

CONCLUSION

Meniscal injuries are common in dogs and typically occur following cranial cruciate rupture. The medial meniscus is usually involved because of its unique anatomic structure. The treatment of choice is primary repair or partial meniscectomy during stifle stabilization. However, even partial meniscectomy inevitably leads to osteoarthritis and a perpetuating cycle of articular cartilage degeneration. Therefore, continued research is warranted to develop methods of improving meniscal blood supply, increasing healing potential through matrix scaffolds, or providing meniscal transplants or prostheses.

REFERENCES

1. Hulse DA, Shires PK: The meniscus: Anatomy, function, and treatment. *Compend Contin Educ Pract Vet* 5:765–777, 1983.
2. Bennett D, May C: Meniscal damage associated with cruciate disease in the dog. *J Small Anim Pract* 32:111–117, 1991.
3. Messner K, Gao J: The menisci of the knee joint: Anatomical and functional characteristics, and a rationale for clinical treatment. *J Anat* 193:161–178, 1998.
4. Williams J, Tomlinson J, Constantinescu GM: Diagnosing and treating meniscal injuries in the dog. *Vet Med* Jan:42–47, 1994.
5. Anoczky SP: Cruciate ligament rupture and associated injuries, in Newton CD, Nunamaker DM (eds): *Textbook of Small Animal Orthopaedics*. Philadelphia, JB Lippincott, 1985, pp 923–939.
6. Ralphs SC, Whitney WO: Arthroscopic evaluation of menisci in dogs with cranial cruciate ligament injuries: 100 cases (1999–2000). *JAVMA* 221: 1601–1604, 2002.
7. Hulse D, Johnson S: Isolated lateral meniscal tear in the dog. *Vet Comp Orthop Trauma* 3:152–154, 1988.
8. Flo GL: Meniscal injuries. *Vet Clin North Am* 23:831–843, 1993.
9. Flo GL: Classification of meniscal lesions in twenty-six consecutive canine meniscectomies. *JAAHA* 19:335–340, 1983.
10. Langley-Hobbs SJ: Lateral meniscal tears and stifle osteochondrosis in three dogs. *Vet Rec* 149:592–594, 2001.
11. Weber NA: Apparent primary ossification of the menisci in a dog. *JAVMA* 212:1892–1894, 1998.
12. Reed AL, Payne JT, Constantinescu GM: Ultrasonographic anatomy of the normal canine stifle. *Vet Radiol Ultrasound* 36:315–321, 1995.
13. Richardson ML, Selby B, Montana MA, Mack LA: Ultrasonography of the knee. *Radiol Clin North Am* 26:63–75, 1988.
14. Cook JL, Tomlinson JT, Kreeger JM, Cook CR: Induction of meniscal regeneration in dogs using a novel biomaterial. *Am J Sports Med* 27:658–665, 1999.
15. Magee T, Shapiro M, Williams D: MR accuracy and arthroscopic incidence of meniscal radial tears. *Skeletal Radiol* 31:686–689, 2002.
16. Helms CA: The meniscus: Recent advances in MR imaging of the knee. *Am J Roent* 179:1115–1134, 2002.
17. Baird DK, Hathcock JT, Rumph PF, et al: Low-field magnetic resonance imaging of the canine stifle joint: Normal anatomy. *Vet Radiol Ultra* 39: 87–97, 1998.
18. DeYoung DJ, Flo GL, Tvedten H: Experimental medial meniscectomy in dogs undergoing cranial cruciate ligament repair. *JAAHA* 16:639–645, 1980.
19. Berjon JJ, Munuera L, Calvo M: Degenerative lesions in the articular cartilage after meniscectomy: Preliminary experimental study in dogs. *J Trauma* 31:342–350, 1991.
20. Cox JS, Nye CE, Schaefer WW, Woodstein IJ: The degenerative effects of partial and total resection of the medial meniscus in dogs' knees. *Clin Orthop* 109:178–183, 1975.
21. Malcolm L, Daniel D: Unpublished data, The biomechanical rationale for partial meniscectomy, IAA meeting, Philadelphia, 1980.
22. King D: The function of the semilunar cartilages. *Br J Bone Joint Surg* 18: 1069–1076, 1936.
23. Simpson DS, Bellenger CR, Ghosh P, et al: The effect of total meniscectomy versus caudal pole hemimeniscectomy on the stifle joint of the sheep. *Vet Comp Orthop Trauma* 12:56–63, 1999.
24. Johnson KA, Francis D, Chu Q, et al: Osteoarthritis induced by medial meniscectomy and caudal pole hemisegmental meniscectomy [ACVS Abstract]. *Vet Surg* 24:39, 1995.
25. Moses PA: A technique for the surgical repair of caudal peripheral detachment and longitudinal peripheral tears of the medial meniscus in dogs. *Vet Comp Orthop Trauma* 2:92–96, 2002.
26. Slocum B, Solcum TD: Meniscal release, in Bojrab MJ, Ellison GW, Slocum B (eds): *Current Techniques in Small Animal Surgery*. Baltimore, Williams & Wilkins, 1998, pp 1197–1199.
27. Gao J, Messner K: Natural healing of anterior and posterior attachments of the rabbit meniscus. *Clin Orthop* 328:276–284, 1996.
28. Hulse DA, Shires P, Abdelbaki YZ, et al: Vascular access channeling to increase meniscal regeneration in the dog. *Vet Surg* 15:414–419, 1986.
29. Shirakura K, Niijima M, Kobuna Y: Free synovium promotes meniscal healing: Synovium, muscle, and synthetic mesh compared in dogs. *Acta Orthop Scand* 68:51–54, 1997.
30. Kobuna Y, Shirakura K, Niijima M: Meniscal repair using a flap of synovium: An experimental study in the dog. *Am J Knee Surg* 8:52–55, 1995.
31. Hidaka C, Ibarra C, Hannafin JA, et al: Formation of a vascularized meniscal tissue by combining gene therapy with tissue engineering. *Tissue Eng* 8: 93–105, 2002.
32. Arnoczky SP, Warren RF, Spivak JM: Meniscal repair using an exogenous fibrin clot: An experimental study in dogs. *J Bone Joint Surg Am* 70A:1209–1217, 1988.
33. Welch JA, Montgomery RD, Lenz SD, et al: Evaluation of small-intestinal submucosa implants for repair of meniscal defects in dogs. *Am J Vet Res* 63: 427–431, 2002.
34. Stone KR, Steadman JR, Rodkey WG, et al: Regeneration of meniscal cartilage with use of a collagen scaffold. *J Bone Joint Surg* 79A:1770–1777, 1997.
35. Stone KR, Rodkey WG, Webber RJ, et al: Future directions: Collagen-based prostheses for meniscal regeneration. *Clin Orthop* 253:129–135, 1990.
36. Rodkey WG, Steadman JR, Li ST: A clinical study of collagen meniscus implants to restore the injured meniscus. *Clin Orthop* 367(suppl):S281–S292, 1999.
37. Kohn D: Autograft meniscus replacement: Experimental and clinical results. *Knee Surg Traumatol Arthrosc* 1:123–125, 1993.
38. Kohn D, Wirth CJ, Reiss G, et al: Medial meniscus replacement by a tendon autograft: Experiments in sheep. *J Bone Joint Surg* 74B:910–917, 1992.
39. Ryu RK, Dunbar WH, Morse GG: Meniscal allograft replacement: A 1-year to 6-year experience. *Arthoscopy* 18:989–994, 2002.
40. Goble EM, Verdonk R, Kane M: Meniscal substitutes: Human experience. *Scand J Sci Sports* 9:146–157, 1999.
41. Peters G, Wirth CJ: The current state of meniscal allograft transplantation and replacement. *Knee* 10:19–31, 2003.
42. Kobayashi M, Toguchida J, Oka M: Preliminary study of polyvinyl alcohol-hydrogel (PVA-H) artificial meniscus. *Biomaterials* 24:639–647, 2003.

ARTICLE #1 CE TEST

This article qualifies for 1.5 contact hours of continuing education credit from the Auburn University College of Veterinary Medicine. Subscribers who wish to apply this credit to fulfill state relicensure requirements should consult their respective state authorities regarding the applicability of this program. To participate, fill out the test form inserted at the end of this issue. To take CE tests online and get real-time scores, log on to ***www.VetLearn.com****.*

1. Which ligament allows increased mobility of the lateral meniscus?

a. cranial tibial
b. caudal tibial
c. caudal femoral
d. intermeniscal

2. What percentage of the meniscus has a blood supply?

a. 10%
b. 25%
c. 40%
d. 50%

3. Which of the following is not a function of the menisci?

a. distributing load across the stifle joint
b. providing sensory information

c. preventing excessive external tibial rotation
d. improving inherent incongruity between the tibial plateau and femoral condyles

4. Injury to the medial meniscus is most commonly associated with
a. cranial cruciate rupture.
b. caudal cruciate rupture.
c. collateral ligament rupture.
d. being hit by a car.

5. In a recent study of lateral meniscal tears identified by arthroscopy, what percentage of stifles had evidence of lateral meniscal damage?
a. 10%
b. 46%
c. 77%
d. 90%

6. Meniscal tears have poor healing potential because of
a. tension created by weight bearing.
b. endogenous collagenases within the joint space.
c. poor blood supply.
d. the severity of most meniscal tears.

7. Which technique for meniscal repair has been associated with fewer degenerative changes?
a. total meniscectomy
b. caudal pole hemimeniscectomy
c. partial meniscectomy
d. meniscal release

8. Hemimeniscectomy is removal of
a. the caudal pole of the meniscus while leaving the cranial pole intact.
b. the cranial pole of the meniscus while leaving the caudal pole intact.
c. only the damaged portion of the meniscus while leaving a normal rim of meniscus intact.
d. the entire meniscus.

9. The meniscal release allows greater mobility of the
a. caudal pole of the medial meniscus.
b. cranial pole of the medial meniscus.
c. cranial pole of the lateral meniscus.
d. caudal pole of the lateral meniscus.

10. Current research has focused on improving the healing potential of the meniscus. Which of the following has been investigated?
a. improving blood supply to the meniscus
b. meniscal allografts
c. biologic matrix scaffolds for meniscal regeneration
d. all of the above