Anesthesia for Companion Birds

Laurel Degernes, DVM, MPH, DABVP (Avian)
North Carolina State University

ABSTRACT: Avian anesthesia has advanced over the past 2 decades. A variety of inhalation and injectable anesthetics have been documented to be safe in widely diverse taxonomic groups. In addition, the ability to maintain and monitor cardiovascular and respiratory parameters within normal physiologic ranges has improved. This article emphasizes concepts and equipment that are applicable for companion avian patients typically seen in veterinary clinics; however, much of this information may also be used for wild bird anesthesia and in field conditions.

Much of the technology developed for small animal anesthesia has been adapted for use in birds, including important advances in patient monitoring. However, because mammals have different anatomy and physiology and a larger body size compared with most birds, there are limitations to the use of this technology in avian anesthesia. This article provides practical information and recommendations for providing and monitoring avian anesthesia in the practice setting. Patient support during anesthesia as well as prevention and management of anesthetic emergencies are also discussed.

PREANESTHETIC CONSIDERATIONS

Before anesthesia, the avian patient should be carefully assessed to ensure that it is a suitable candidate for the planned procedure. Preanesthetic assessment should include a history and thorough physical examination. In particular, the heart and respiratory system should be auscultated; the crop palpated for food or liquid; the abdomen palpated for organ enlargement, eggs, or other masses; and the nutrition and hydration status assessed. Depending on the indications for anesthesia and the patient's health status, preanesthetic laboratory tests may include a complete blood count, biochemistry profile, fecal Gram stain, cloacal culture, and radiography. The risk of severe complications or death is generally low during avian anesthesia when inhalation agents such as isoflurane or sevoflurane are used; however, it is always important to warn the bird's owner of potential risks, verbally and in writing, before the planned procedure. The risk of complications increases when sick or injured birds are anesthetized or the surgical procedure is prolonged.[1] Sick or injured birds, in particular, should be stabilized with warmed fluids, supplemental heat, and antibiotics as needed before anesthesia.[2]

Preanesthetic fasting can be controversial in avian practice. Some authors recommend fasting birds for no longer than 2 to 3 hours,[3] but I have found that longer fasting periods are necessary for adequate crop and proventriculus emptying and are well tolerated by stabilized avian patients. A general guideline for fasting birds before anesthesia is 8 to 12 hours for medium or larger birds (>300 g) and 3 to 6 hours for smaller birds.[4] Preanesthetic sedatives and other drugs are rarely used in birds, with the exception of analgesics (e.g., butorphanol). Anticholinergic drugs such as atropine are not routinely administered to birds because thickened respiratory tract secretions increase the

risk of airway or endotracheal tube occlusion.[5] Lastly, it is important to organize all necessary supplies, equipment, and emergency drugs before starting anesthesia and surgery.

ANESTHESIA SUPPLIES AND EQUIPMENT

Isoflurane and Sevoflurane

Inhalation anesthesia is more commonly used than injectable anesthesia in clinical avian practice. Isoflurane is currently the anesthetic agent of choice, although sevoflurane is also an excellent, albeit more expensive, option.[6] Respiratory depression and hypoventilation are potential complications of both agents, so capnography should be used to monitor ventilatory status, particularly in birds that are breathing spontaneously.[7,8] The advantages of using sevoflurane versus isoflurane in birds include faster induction and recovery due to decreased blood and tissue solubility and smoother recoveries with less ataxia.[6,9] In practice, however, sevoflurane anesthesia may not always result in a faster or smoother recovery. Possible explanations for prolonged recovery may include hypotension, acid–base imbalance, and hypoxemia. A situation in which recovery from sevoflurane anesthesia might not be smooth is when an avian patient undergoes a painful procedure and postoperative analgesia is inadequate. Rapid emergence from an anesthetic state coupled with pain can result in a rough recovery. Further clinical research is needed to account for these unexpected observations.

In my experience, birds are usually induced and maintained at 3% to 4% and 1% to 2.5%, respectively, for isoflurane and 4% to 6% and 3% to 4%, respectively, for sevoflurane. An oxygen flow rate of 150 to 200 mL/kg/min is commonly reported,[3] but I typically use a rate of 1 L/min in most medium and large birds (approximately >300 g). Induction and uncomplicated recovery generally take less than 5 minutes each. Inhalation anesthesia induction is more rapid in birds than mammals because of the greater lung surface area and an efficient cross-current gas exchange in the air capillaries.[10] Likewise, small changes in vaporizer settings can produce dramatic changes in patient response, so careful monitoring is necessary. Recovery can be prolonged with procedures longer than about 45 minutes or when the patient is compromised by hypothermia, respiratory acidosis, hypovolemia, or other metabolic disturbances. During induction, the bird is manually restrained until immobilized and then placed in a recumbent position on a padded surface. During recovery, the bird is gently restrained in a towel and extubated once it starts to resist the presence of the tube, but oxygen is administered via an open mask until the bird is recovered from anesthesia and able to stand. Further recovery is done in a cardboard box or in a smooth-walled cage in a darkened room. I recommend against placing parrots in a regular cage for at least an hour after anesthesia to avoid possible injury from climbing and falling.

Gentle intubation with an uncuffed endotracheal tube is important in birds because of the presence of complete tracheal rings.

Injectable Anesthetic Agents

Injectable anesthetics, such as propofol or medetomidine–ketamine (followed by reversal with atipamezole), may be useful for remote field locations where commercial shipment of hazardous gases and anesthetic agents is logistically complicated or prohibited[11,12] or for use in large birds for which mask induction may be challenging (i.e., ratites).[13] More information related to injectable anesthetic options in birds can be found elsewhere.[5,6,14–16]

Local Anesthetic Agents

Local anesthetics block ion channels to prevent pain impulse generation and conduction, and they should be combined with general anesthesia when used in birds to reduce handling stress. Lidocaine can be used preoperatively (maximum recommended dose: ≤4 mg/kg to prevent toxicosis).[17] Bupivacaine (2 mg/kg) at the site of incision or as a ring block may provide postoperative analgesia.[11]

Masks

Commercially available masks designed for dogs and cats can be used for induction of avian anesthesia. The black rubber gasket is replaced with a latex glove that is tied or taped over the opening (Figure 1), and a

Laurel Degernes, DVM, MPH, DABVP (Avian)

Figure 1. Commercially available anesthesia masks are adapted for use in birds by replacing the black rubber gasket with a disposable latex glove. Other options shown include a modified small food container and a cut-down 35-mL syringe case.

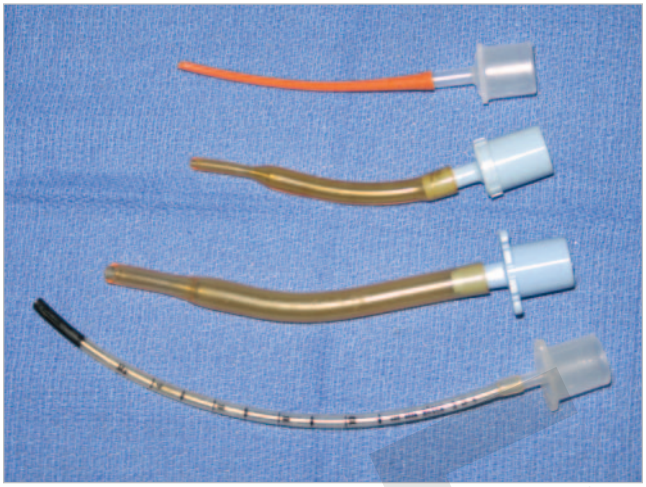

Laurel Degernes

Figure 2. Uncuffed endotracheal tubes (bottom tube) are used in birds to prevent tracheal necrosis. Commercially available endotracheal tubes are not always available for smaller avian patients, so red rubber catheters can be modified for use (top tube). Pediatric Cole tubes (middle two tubes) are available in multiple sizes (8 to 22 Fr) and provide an excellent seal at the glottis.

small oval is cut into the latex glove. During mask placement, the handler restrains the bird's head while the anesthetist spreads the opening for the mask to place it over the bird's head. The advantage of using a latex glove for the gasket is that if the patient (e.g., a parrot with a large beak) bites the glove, it is simple and inexpensive to replace. The latex glove forms a good seal around the patient's neck to prevent waste gas from escaping, and when the procedure is completed, the latex glove is discarded and the mask disinfected before use on the next patient. A properly sized mask allows the entire head and beak to be inserted while minimizing dead space.

Masks can be modified to accommodate the widely diverse anatomic variations of avian species. For example, for budgerigars and finches, a cut-down 35- or 60-mL syringe case can be used, with a hole drilled at the closed end to facilitate insertion of the adapter piece for the circuit (Figure 1). At the other extreme, a 1- to 2-liter soft drink bottle can be cut down to facilitate masking a large toucan. Other examples of homemade masks include urine specimen cups and small, plastic food containers.

Endotracheal Tubes and Intubation

Birds should be intubated for procedures that will last longer than 30 minutes. Intubation is done after the patient is in a medium plane of anesthesia (no muscle tone or response to a toe pinch). The tube should provide a good seal but should not be tight within the trachea. Cuffed endotracheal tubes should be avoided because of the presence of complete tracheal rings.[10] I prefer using pediatric Cole tubes for intubating birds such as parrots, pigeons, and most raptors because these tubes provide a good seal at the glottis (Figure 2). The disadvantage of these tubes is that only 1.5 to 2 cm of tube is inserted into the trachea, so it is important to carefully tape the tube in place (Figure 3). Uncuffed endotracheal tubes provide a suitable alternative to Cole tubes. Suitably sized endotracheal tubes for birds weighing less than 100 g are not commercially available. Red rubber feeding tubes can be cut down, beveled, and sanded smooth, but great caution should be exercised when using small tubes in birds because of possible mucus occlusion during surgery.

The glottis is located at the caudal aspect of the tongue. Intubation is facilitated by the holder opening the upper and lower beak and pushing dorsally on the tongue from underneath the intermandibular space, while the anesthetist grasps the tongue to pull it rostrally for tube placement. It is important to remember to slide the tongue and tube back into the oral cavity after intubation, as the tongue can slide off a short tube (e.g., a Cole tube). Once the bird is intubated, the tube is securely taped to the mandible and the neck is extended

Laurel Degernes

Figure 3. Intubated green conure with the endotracheal tube taped to the mandible. After intubation, it is important to securely tape the anesthesia circuit to the table to prevent the endotracheal tube from being inadvertently dislodged from the trachea.

to prevent kinking of the trachea. Capnography is extremely useful for monitoring proper ventilation during anesthesia. If the bird develops hypercapnia or dyspnea or if the expiratory phase is prolonged, endotracheal tube kinking or obstruction should be ruled out. During intubation, the patient must be handled very gently to prevent trauma to the trachea, as severe tracheal necrosis with associated fibrosis and stenosis may develop.[18] These changes may not be apparent until weeks to months after surgery, when the bird becomes dyspneic.

Breathing Circuits

Nonrebreathing circuits, such as the Bain circuit or modified Jackson-Rees circuit (i.e., Ayre's T-piece), rely on a high flow rate to eliminate carbon dioxide, typically more than 200 mL oxygen/kg/min.[19] The advantages of these circuits include decreased resistance to breathing by the patient and rapid responses to changes in the vaporizer setting. A 0.5- to 1.0-L bag is used for most birds. The entire circuit should be disinfected and dried between patients to prevent disease transmission.

Mechanical Ventilators

Mechanical ventilators that are suitable for patients as small as cockatiels are available. Ventilators can be pressure limited or volume limited. Pressure-limited ventilators deliver a tidal volume until a predetermined airway pressure is reached, while volume-limited ventilators deliver a predetermined tidal volume regardless of airway pressure. A peak inspiratory pressure of 5 cm H_2O was used in African grey parrots undergoing mechanical ventilation during isoflurane anesthesia in one study.[20] If an endotracheal tube is occluded, a pressure-limited ventilator will deliver a lower tidal volume and the patient will be underventilated. Under the same circumstances, a volume-limited ventilator will trigger an alarm when the airway pressure exceeds a certain limit. In another study, pigeons anesthetized with isoflurane anesthesia and ventilated with a pressure-limited ventilator developed respiratory alkalosis after the coelomic cavity was opened. With this "open system," the ventilator could not achieve the predetermined pressure and the birds were overventilated.[21] Use of a volume-limited ventilator under these circumstances would be less likely to cause acid–base derangements. Regardless of ventilator type, if the patient is monitored by capnography, hypercapnia secondary to poor ventilation can be quickly recognized and corrected.

Manual Ventilation

An alternative to mechanical ventilation is manual ventilation, or *bagging*. Airway pressures should not exceed 15 to 20 cm H_2O to prevent overinflation of air sacs.[4] From a practical perspective, the clinician should be able to observe the rise and fall of the keel without any audible noises from the patient during bagging. Manual respiration should be employed when a bird is breathing shallowly or becomes apneic or hypercapnic.

ANESTHESIA MONITORING

The key to effective anesthesia monitoring is a dedicated anesthetist who is assigned to monitor the patient throughout the anesthesia period. No single monitor covers all the possible parameters, and individual preferences and resource availability often dictate the types of monitoring used for avian anesthesia.

Basic Parameters

At a minimum, heart and respiratory rates and rhythms should be monitored using a stethoscope and visual observation. The bell of the stethoscope should be placed under the feathers in direct contact with the skin. For heart auscultation, suitable places to listen with minimal sound muffling include the keel bone, the thoracic inlet, the axillae, and the back on either side of the spine. Heart rates may be difficult to count in small birds and vary widely between species. The length and depth of anesthesia also affect heart and respiratory rates. Rather than using a published heart rate for a par-

ticular species, it is more important to assess the rate, rhythm, and intensity of sound throughout the procedure as a guide to patient status during anesthesia. Likewise, respiratory rates vary widely between species, so it is more important to monitor the individual patient's changes in respiratory rate and depth. Use of clear plastic surgical drapes facilitates visual monitoring of the respiratory rate. It is important to ventilate the bird at least once per minute throughout anesthesia to prevent hypoventilation and possible respiratory acidosis. More frequent ventilation (approximately six to 10 breaths per minute) may be necessary if the depth of respiration is very shallow or if the bird becomes dyspneic.

Central Nervous System

Assessment of certain reflexes can assist in determining the anesthetized patient's plane of anesthesia.[19,22] Pain reflexes (i.e., toe pinch or feather pluck) are lost when the bird is in a medium (surgical) plane of anesthesia.[22] Palpebral reflexes are usually lost by a medium plane of anesthesia, but corneal reflexes persist until the deep plane of anesthesia.[19] The presence of a mask over the bird's head usually interferes with the ability to assess ocular reflexes, but the loss of muscle tone in the legs or wings can be useful for assessing transition from a light to a medium plane of anesthesia.[19] Generally, the heart and respiratory rates increase when the bird is experiencing pain or when the depth of anesthesia is too low; conversely, these rates may decrease in the deep plane of anesthesia, signaling the need to adjust the flow of anesthetic gases accordingly.[19,22]

Circulatory System

Ultrasonic Doppler Monitoring

The ultrasonic Doppler flow detector is an excellent device for monitoring heart rate and rhythm. An ultrasonic beam is transmitted into the artery and is reflected by erythrocytes onto a receiving transducer. The difference in frequency between the transmitted and reflected beams is linearly proportional to the rate of blood flow in the vessel and therefore can be used to develop an audible signal proportional to flow rate.[22] The sensor is commonly placed over the cranial tibial artery, palpable on the cranial aspect of the hock joint; the superficial ulnar artery, palpable on the ventral surface of the elbow joint (Figure 4); or the deep radial artery, palpable on the ventral surface of the distal radius near the carpal joint. The sensor is taped to the preferred location, or, for the wing locations, secured in place by a pair of tongue depressors taped together at one end to form an atraumatic "clip"[22] (Figure 4). The most common problems with correct sensor placement are occlusion of the artery by applying too much pressure over it (i.e., taping the sensor too securely) and inadequate contact with the skin over the artery due to insufficient gel or failure to move or remove feathers at the site. The audible signal can become faint or disappear if the sensor is dislodged or cardiovascular depression occurs.

Philip Ruckart, North Carolina State University

Figure 4. Anesthetized blue and gold macaw being monitored with an ultrasound Doppler flow detector, capnograph, and cloacal temperature probe. The Doppler sensor is being held in place by a pair of tongue depressors acting as an atraumatic clip, and the capnograph is set up to sample expired breaths via a port incorporated into the endotracheal tube.

Ultrasonic Doppler flow detectors can also be used for indirect blood pressure (BP) monitoring. Direct BP monitoring is difficult in most birds because of their small, relatively inaccessible arteries. Indirect BP measurements are a useful, inexpensive alternative and can provide systolic BP values and trend changes during anesthesia. Indirect BP measurements have been found to correlate well with direct BP measurements in anesthetized ducks.[7,23] The ultrasonic Doppler flow detector sensor is positioned over one of the locations mentioned previously, and a small BP cuff is placed on the limb proximal to the sensor (i.e., distal humerus or distal femur). The cuff width should be approximately 40% of the circumference of the wing or leg; for example, a #1 cuff is appropriate for cockatiels, a #2 cuff for African grey parrots, and a #3 cuff for larger cockatoos.[24] The cuff is inflated until the Doppler signal is no longer audible. As pressure is slowly released from the cuff, the systolic pressure (in mm Hg) is recorded from the sphygmomanometer when the heartbeat becomes audible again. The normal mean systolic BP for eight species

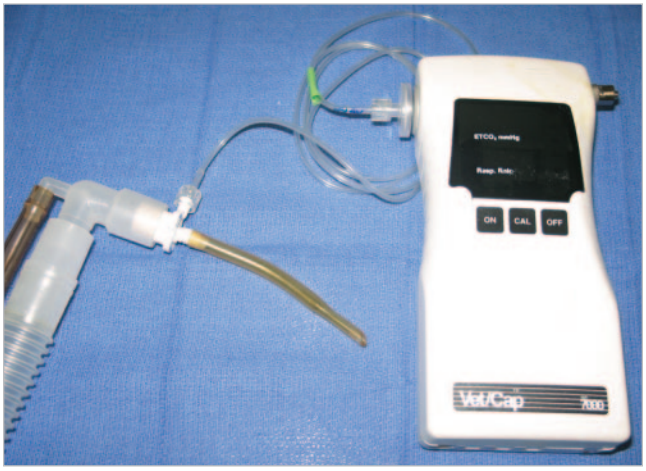

Laurel Degernes

Figure 5. Capnometer with tubing connected to a sidestream adapter that is connected to an endotracheal (Cole) tube and nonrebreathing circuit. The sidestream adapter at the base of the endotracheal tube contributes minimal dead space to the anesthesia circuit.

of psittacines while awake was 139 mm Hg (range: 113 to 157 mm Hg); during isoflurane anesthesia, it was 107 mm Hg (range: 96 to 140 mm Hg).[24]

Esophageal Stethoscope Monitoring

A simple esophageal heart rate monitor may be substituted for stethoscope monitoring in birds that have simple crop anatomy (i.e., waterfowl, raptors, most aquatic and wading birds), but not in parrots and pigeons.[22] The monitor is placed in the portion of the esophagus caudal to the thoracic inlet.

Electrocardiography

The application of electrocardiography for monitoring avian anesthesia has the benefits of recording heart rates that are too rapid to count manually and providing specific information about cardiovascular abnormalities or arrhythmias that may be present in the anesthetized patient. Electrodes are positioned at the patagium and inguinal skin web locations using flattened alligator clips, or small hypodermic needles are passed though the skin and attached to alligator clips.[25]

Respiratory System and Ventilatory Status

Capnography

The anesthetized patient's ventilatory and circulatory status is effectively monitored using capnography. In my opinion, short of ensuring that the heart is still beating and the bird is still breathing (or being ventilated manually or mechanically), this is the most important tool for monitoring the avian patient during anesthesia. This noninvasive method measures the respiratory rate and partial pressure of end-tidal carbon dioxide ($ETCO_2$) and indirectly estimates the partial pressure of arterial carbon dioxide ($PaCO_2$). Sidestream monitors are recommended for use in birds and other small patients because they contribute minimal dead space to the anesthesia circuit (Figure 5). Capnometers are available with or without capnographic waveform displays. The former are more expensive but provide a visual display of $ETCO_2$ changes, which is important in determining the accuracy of the airflow readings.

An $ETCO_2$ of 30 to 45 mm Hg should indicate adequate ventilation during inhalation anesthesia in most parrots and approximates a normal physiologic range of 25 to 40 mm Hg for $PaCO_2$ for awake birds.[20] If the $ETCO_2$ level exceeds approximately 45 mm Hg, increasing the ventilatory rate should facilitate a return to the normal range, assuming that the endotracheal tube is patent and the trachea is not obstructed. If the bird's respiratory rate is normal but its breaths are shallow, the bird can become hypercapnic and should be ventilated at least once or twice per minute or as needed to maintain the $ETCO_2$ within the normal range.[20] At the other extreme, excessive ventilation can "blow off" CO_2, resulting in an $ETCO_2$ that is below the recommended range. Failure to maintain $ETCO_2$ below the upper limit of the normal physiologic range may result in development of respiratory acidosis.

Pulse Oximetry

Pulse oximetry is a noninvasive method of estimating arterial oxygen status. It offers advantages such as real-time monitoring of arterial oxygen saturation and heart rate, but due to different absorption characteristics of hemoglobin in birds compared with mammals, the pulse oximeter has a tendency to underestimate values at low oxygen saturation levels.[26] Motion artifact is another complication with this technology, particularly for surgical procedures involving patient manipulation (i.e., orthopedic procedures or laparoscopy). The sensor is placed over unfeathered locations, such as nonpigmented toes or lower legs.[26] It is important to note that a patient can be well oxygenated (especially during inhalation anesthesia) yet still be hypercapnic, so monitoring $ETCO_2$ is very important, as discussed previously. While I do not recommend acquisition of a pulse oximeter specifically for avian anesthesia monitoring, if a practice owns one already, it can be beneficial for mon-

itoring rapid avian heart rates (up to 500 bpm) and trends in oxygen saturation.

Temperature

Birds generally have a higher core body temperature than mammals but are prone to heat loss from the comparatively larger surface area relative to body mass.[27] Radiant and conductive heat loss can occur from loss of insulation (removal or plucking of feathers), preparation and moistening of surgical sites, and use of room-temperature fluids and anesthetic gases. Perianesthetic drugs can also interfere with normal thermoregulation. The patient's core body temperature should be monitored throughout anesthesia via a cloacal or esophageal temperature probe.[28] Avian esophageal and cloacal temperatures are well correlated in studies that compared the two sites[29]; however, cloacal temperature probes are prone to being dislodged or recording a cooler temperature if they are not secured appropriately within the cloaca.

ROUTINE PATIENT SUPPORT DURING ANESTHESIA

Fluid Therapy

Fluid therapy is a critical component of avian anesthesia, particularly for procedures lasting longer than 30 minutes. Ideally, an intravenous or intraosseous (IO) catheter is placed to facilitate fluid administration; however, subcutaneous fluid administration may be adequate for routine or relatively short procedures in otherwise stable patients.[30] Subcutaneous fluids can be administered in the ventral skin web between the femur and body wall or in the interscapular space over the back, on either side of the spine. Intravenous catheters can be placed in the jugular vein (the right jugular vein is typically larger in birds), the basilic vein on the ventral humerus, or the medial metatarsal vein on the distal leg.[30] A 24-gauge over-the-needle Teflon catheter works well in birds weighing more than approximately 250 g. Alternatively, a butterfly catheter can be taped in place or a regular hypodermic needle can be used for a single bolus administration. An intraosseous catheter can be placed in the distal ulna or proximal tibiotarsus for fluid administration.[31] This technique is commonly used in small birds, when intravenous access is limited by the size of the vein, or when the veins are preserved for other purposes. The fluids should be warmed to approximately 101°F to 105°F (38.3°C to 40.5°C) and administered as a continuous infusion (especially for sick or debilitated surgical patients) or as a bolus at the beginning and end of anesthesia.[5]

Heat

Hypothermia can lead to prolonged anesthesia recovery, metabolic acidosis, and death.[28] Birds deprived of thermal support during isoflurane anesthesia can lose 3°C to 3.5°C within 40 minutes,[29] and the expected rate of heat loss is even higher if the coelomic cavity is exposed in birds that are not being provided supplemental heat. Birds become hypothermic during anesthesia even when supplemental heat is provided from circulating hot water blankets, mechanical ventilators with heated air, or infrared heat emitters.[29,32–33] Radiant heat sources and forced-air warmer systems (e.g., Bair Hugger Warming System [Augustine Medical, Eden Prairie, MN]) appear to be the most suitable for helping maintain core body temperature within an acceptable clinical range in anesthetized birds.[29,32] Use of transparent plastic surgical drapes can also aid in trapping heat next to the patient, but supplemental heat is still required to aid in thermoregulation.[32] Hyperthermia, although rare during anesthesia, can develop as a result of equipment malfunction (i.e., excessive heat generation from an operating lamp)[34] or when working with well-insulated aquatic birds acclimated to northern temperatures.

Anesthetized birds under inhalation anesthesia may be well oxygenated yet hypercapnic; therefore, monitoring end-tidal carbon dioxide is essential during anesthesia.

Analgesia

Preoperative analgesics, such as butorphanol, are indicated for painful surgical procedures and may decrease the level of anesthesia required during surgery as well as provide analgesia after surgery.[35] Other options include NSAIDs such as ketoprofen, carprofen, or meloxicam.[17,36] Species variability to possible nephrotoxic effects of NSAIDs may exist[11]; therefore, it is important to ensure that the bird is well hydrated and has normal

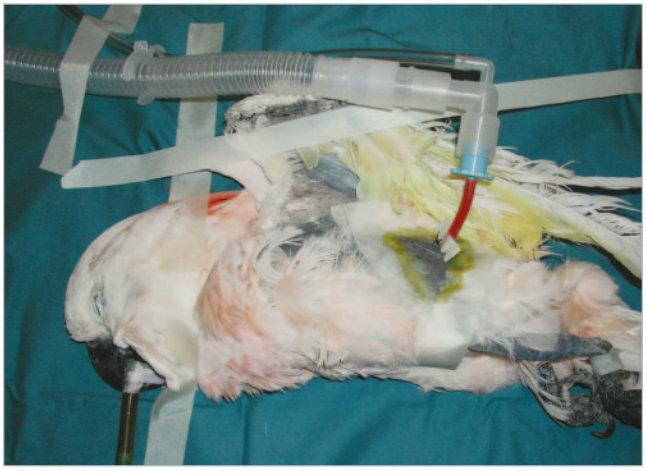

Laurel Degernes

Figure 6. Anesthetized Moluccan cockatoo in lateral recumbency, with a cannula placed in the left caudal thoracic air sac and secured in place with a butterfly tape tab and two sutures. The anesthesia circuit is connected to an adapter on the cannula, and the bird is being maintained under anesthesia using positive pressure ventilation.

renal function. More information related to preventing and managing avian pain is available in two review articles.[17,37]

ANESTHETIC EMERGENCIES AND COMPLICATIONS

Respiratory Emergencies

Respiratory emergencies involving apnea are not uncommon during inhalation anesthesia, especially during procedures lasting longer than 30 to 40 minutes; however, they generally have a good prognosis if corrective steps are initiated promptly. If an endotracheal tube is not already in place, one should be inserted and manual or mechanical ventilation initiated at a rate of 10 to 12 breaths/min or as indicated using capnographic monitoring. The level of gas anesthesia may be reduced, if indicated, but not necessarily reduced to zero. Apnea is commonly reported in aquatic birds and is thought to be related to their diving physiology. Management of apnea in these birds is usually transient and similar to that for companion birds.[38] Doxapram can be administered for respiratory depression or during cardiopulmonary resuscitation (5 to 20 mg/kg IM, IV, or IO).[39]

Air Sac Cannula

It is important for avian practitioners to know how to place an air sac cannula as an alternative "breathing tube" in the event of an obstruction of the trachea, syrinx, or major bronchi caused by a foreign body, granuloma, or other mass. Other indications for placement of an air sac cannula are surgeries or procedures involving the beak or oral cavity, where an endotracheal tube may be in the way of the procedure. An air sac cannula placed in the caudal thoracic air sac and connected to the anesthesia circuit is an effective tool for maintaining anesthesia[40] (Figure 6). While the air sacs themselves play no role in gas exchange, they are important in providing a reservoir for air movement across the lungs. Air from the air sacs travels through the parabronchi (tertiary bronchi) into the air capillaries, where gas exchange occurs.[41]

There are a number of air sac cannula options, including shortened endotracheal tubes, balloon-tipped Foley catheters, red rubber feeding tubes, and commercially available air sac cannulas with an attached disk for securing to the skin (Avian Air Sac Surgical Catheter or Avian Air Sac Tube with retention disk [Benson Medical Industries, Markham, Ontario]). In my experience, red rubber feeding tubes are advantageous because they are inexpensive, sterile, and blunt-tipped; have at least two side ports; and come in a variety of diameters. The cannula should approximate the bird's trachea in diameter and be 7 to 10 cm in length.

Placement of an air sac cannula requires that the bird be anesthetized, usually via mask induction of inhalant anesthesia. The patient is placed in right or left lateral recumbency, the wings are extended and taped dorsally, and the legs are pulled caudally (or cranially, if the air sac cannula is to be placed behind the leg). The feathers are plucked in a 3 cm–diameter area caudal to the last rib, cranial to the quadriceps muscles over the femur, and ventral to the lateral spinal processes. The feathered margins are taped, the skin aseptically prepped with 1% betadine solution, and the surgical site draped. A small skin incision (~0.5 cm) is made in the space (or between the last two ribs). A mosquito forceps is used to bluntly dissect through the muscle layers until the tips of the forceps "pop" into the air sac space. Gently spreading the jaws of the forceps facilitates passage of the cannula into the air sac. The tube is inserted approximately 2 cm in most medium-sized birds (300 g). Correct positioning of the cannula can be verified by holding a small downy feather at the opening to the cannula while the anesthetist ventilates the bird. If there is no air movement through the tube, make sure that the tube has passed through the peritoneum and is not in the ventral groin web or pushed against the gastrointestinal organs. Slight tube rotation or repositioning can sometimes be success-

ful. The tube is secured to the skin using a "finger trap" suture or a small butterfly tab and two simple interrupted sutures. If the air sac cannula is to be used to deliver anesthetic gas, an adapter is added to the cannula for connection to the anesthesia circuit. When an air sac cannula is placed in a dyspneic bird, the anesthesia circuit should be quickly moved from the anesthesia mask to the cannula because the bird can awaken rapidly while breathing room air via the cannula.

Placing an air sac cannula in a dyspneic bird gives the clinician some time to address the underlying obstruction (i.e., perform endoscopic examination or remove a tracheal foreign body) or respiratory disease. Cannulas can be left in place for several days if the patient is hospitalized and being managed with appropriate antimicrobials. Occasionally, an air sac cannula will become obstructed if air sacculitis is present, so the bird must be carefully monitored for potential complications. If a cannula is placed to facilitate beak or oral surgery, it is removed at the end of surgery, and the incision is allowed to heal by second intention.

Cardiac Emergencies

If bradycardia develops, the anesthetist must assess whether it represents a true emergency or is a transient, normal response observed in some diving birds.[38] If bradycardia develops in a nonaquatic bird, the level of inhalant anesthesia should be reduced.[38] Anticholinergic agents such as atropine can be used to increase the heart rate.[5] Maintaining adequate respiration is important because cardiac arrest usually follows apnea within several minutes; however, if apnea is promptly addressed, cardiac arrest is uncommon.[5] If cardiac arrest and apnea occur simultaneously, successful resuscitation is unlikely. Cardiac arrest without apnea is uncommon during avian anesthesia, but the prognosis for recovery is poor for avian patients that go into cardiac arrest.[5] The solid keel interferes with effective cardiac massage, although in the event of cardiac arrest, attempts should be made to compress the sternum at a rate of 60 to 100 compressions/min. Emergency drugs, including epinephrine (1:1000; 0.5 to 1.0 mg/kg IM, IV, IO, or intratracheal), atropine (0.5 mg/kg IM, IV, IO, or intratracheal), and doxapram, should also be administered.[39] A set of emergency drugs should be available during anesthesia or surgery.

Hypotension

Hypotension, defined as systolic BP less than 90 mm Hg, can develop secondary to several conditions during anesthesia, including cardiovascular depression caused by the anesthetic agent or hypovolemia related to dehydration or blood loss.[22] Identification and correction of the underlying cause should be initiated immediately. The level of anesthesia should be reduced, rate of fluid administration increased, and core body temperature assessed and addressed as needed. Warmed IV or IO bolus crystalloid fluid administration (10 mL/kg) is indicated for hypovolemic birds and can be repeated if necessary to increase systolic BP to more than 90 mm Hg.[23] Synthetic colloid solutions (i.e., hetastarch [Abbott Laboratories, North Chicago, IL], 10 mL/kg IV) may be used for plasma expansion and treatment of hypovolemia in birds that are hypoproteinemic or in birds that have suffered acute blood loss during surgery.[5] Blood transfusions may also be indicated for acute blood loss.[23]

REFERENCES

1. LaBonde J, Michel C. Anesthesia monitoring and intraoperative support of the avian patient. *Proc Assoc Avian Vet* 1995:271-274.
2. Harrison GJ, Lightfoot TL, Flinchum GB. Emergency and critical care. In: Harrison GJ, Lightfoot TL, eds. *Clinical Avian Medicine*; vol 1. Palm Beach, FL: Spix Publishing; 2006:214-232.
3. Edling TM. Anesthesia and monitoring. In: Harrison GJ, Lightfoot TL, eds. *Clinical Avian Medicine*; vol 2. Palm Beach, FL: Spix Publishing; 2006:747-760.
4. Abou-Madi N. Avian anesthesia. *Vet Clin North Am Exotic Anim Pract* 2001;4(1):147-167.
5. Gunkel C, Lafortune M. Current techniques in avian anesthesia. *Semin Avian Exotic Pet Med* 2005;14(4):263-276.
6. Heard DJ. Avian anesthesia: present and future trends. *Proc Assoc Avian Vet* 1997:117-122.
7. Ludders JW, Mitchell GS, Rode J. Minimal anesthetic concentration and cardiopulmonary dose response of isoflurane in ducks. *Vet Surg* 1990;19(4):304-307.
8. Naganobu K, Miyamoto T, Hagio M. Sevoflurane anaesthesia in chickens during spontaneous and controlled ventilation. *Vet Rec* 2003;152:45-48.
9. Quandt JE, Greenacre CB. Sevoflurane anesthesia in psittacines. *J Zoo Wildl Med* 1999;30(2):308-309.
10. Orosz SE. The avian respiratory system. *Compend Contin Educ Pract Vet* 1999;21(10):935-943.
11. Mulcahy DM, Tuomi P, Larsen RS. Differential mortality of male spectacled eiders (*Somateria fischeri*) and king eiders (*Somateria spectabilis*) subsequent to anesthesia with propofol, bupivacaine, and ketoprofen. *J Avian Med Surg* 2003;17:117-123.
12. Machin KL, Caulkett NA. Evaluation of isoflurane and propofol anesthesia for intraabdominal transmitter placement in nesting female canvasback ducks. *J Wildl Dis* 2000;36(2):324-334.
13. Lin HC, Todhunter PG, Powe TA, Ruffin DC. Use of xylazine, butorphanol, tiletamine-zolazepam, and isoflurane for induction and maintenance of anesthesia in ratites. *JAVMA* 1997;210(2):244-248.
14. Sandmeier P. Evaluation of medetomidine for short-term immobilization of domestic pigeons (*Columba livia*) and Amazon parrots (*Amazona* species). *J Avian Med Surg* 2000;14(1):8-14.
15. Lumeij JT, Deenik JW. Medetomidine-ketamine and diazepam-ketamine anesthesia in racing pigeons (*Columba livia*)—a comparative study. *J Avian Med Surg* 2003;17(4):191-196.

16. Uzan M, Onder F, Atalan G, et al. Effects of xylazine, medetomidine, detomidine, and diazepam on sedation, heart and respiratory rates, and cloacal temperature in rock partridges (*Alectoris graeca*). *J Zoo Wildl Med* 2006;37(2):135-140.
17. Machin KL. Controlling avian pain. *Compend Contin Educ Pract Vet* 2005;27(4):299-309.
18. de Matos REC, Morrisey JK, Steffey M. Postintubation tracheal stenosis in a blue and gold macaw (*Ara ararauna*) resolved with tracheal resection and anastomosis. *J Avian Med Surg* 2006;20(30):167-174.
19. Heard DJ. Anesthesia and analgesia. In: Altman RB, Clubb SL, Dorrestein GM, Quesenberry K, eds. *Avian Medicine and Surgery*. Philadelphia: Saunders; 1997:807-827.
20. Edling TM, Degernes LA, Flammer K, Horne WA. Capnographic monitoring of anesthetized African grey parrots receiving intermittent positive pressure ventilation. *JAVMA* 2001;219(12):1714-1718.
21. Touzot-Jourde G, Hernandez-Divers SJ, Trim CM. Cardiopulmonary effects of controlled versus spontaneous ventilation in pigeons anesthetized for coelioscopy. *JAVMA* 2005;227(9):1424-1428.
22. Heard D. Perioperative supportive care and monitoring. *Vet Clin North Am Exotic Anim Pract* 2000;3(3):587-615.
23. Lichtenberger M, Orcutt C, DeBehnke D, et al. Mortality and response to fluid resuscitation after acute blood loss in mallard ducks. *Proc Assoc Avian Vet* 2003;65-70.
24. Lichtenberger M, Loose N, Goodman M. Normal indirect blood pressure in different species of birds. *Proc Assoc Avian Vet* 2005;15-17.
25. Nap AMP, Lumeij JT, Stokhof AA. Electrocardiogram of the African grey (*Psittacus erithacus*) and Amazon (*Amazona* spp.) parrot. *Avian Pathol* 1992;21:45-53.
26. Schmitt PM, Gobel T, Trautvetter E. Evaluation of pulse oximetry as a monitoring method in avian anesthesia. *J Avian Med Surg* 1998;12(2):91-99.
27. Dawson WR, Whittow GC. Regulation of body temperature. In: Whittow GC, ed. *Sturkie's Avian Physiology*. 5th ed. San Diego: Academic Press; 2000:343-390.
28. Phalen DN, Lau MT, Filippich LJ. Considerations for safely maintaining the avian patient under prolonged anesthesia. *Proc Assoc Avian Vet* 1997:111-116.
29. Phalen DN, Mitchell ME, Cavazos-Martinez ML. Evaluation of three heat sources for their ability to maintain core body temperature in the anesthetized avian patient. *J Avian Med Surg* 1996;10(3):174-178.
30. Abou-Madi N, Kollias GV. Avian fluid therapy. In: Kirk RW, Bonagura JD, eds. *Current Veterinary Therapy XI*. Philadelphia: Saunders; 1992:1154-1159.
31. Ritchie BW, Otto CM, Latimer KS, Crowe DT. A technique for intraosseous cannulation for intravenous therapy in birds. *Compend Contin Educ Pract Vet* 1990;12(1):55-58.
32. Rembert MS, Smith JA, Hosgood G, et al. Comparison of traditional thermal support devices with the forced-air warmer system in anesthetized Hispaniolan Amazon parrots (*Amazona ventralis*). *J Avian Med Surg* 2001;15(3):187-193.
33. Boedeker NC, Carpenter JW, Mason DE. Comparison of body temperatures of pigeons (*Columba livia*) anesthetized by three different anesthetic delivery systems. *J Avian Med Surg* 2005;19(1):1-6.
34. Hofmeister EH, Hernandez-Divers SJ. Anesthesia case of the month. *JAVMA* 2005;227(5):718-720.
35. Curro TG, Brunson DB, Paul-Murphy J. Determination of the ED_{50} of isoflurane and evaluation of the isoflurane-sparing effect of butorphanol in cockatoos (*Cacatua* spp). *Vet Anesth* 1994;23:429-433.
36. Machin KL, Livingston A. Assessment of the analgesic effects of ketoprofen in ducks anesthetized with isoflurane. *Am J Vet Res* 2002;63(6):821-826.
37. Machin KL. Avian pain: physiology and evaluation. *Compend Contin Educ Pract Vet* 2005;27(2):98-109.
38. Degernes LA, Harms CA, Golet GH, Mulcahy DM. Anesthesia and liver biopsy techniques for pigeon guillemots (*Cepphus columba*) suspected of exposure to crude oil in marine environments. *J Avian Med Surg* 2002;16(4):291-299.
39. Carpenter JW. *Exotic Animal Formulary*. 3rd ed. St. Louis: Elsevier Saunders; 2005.
40. Jaensch SM, Cullen L, Raidal SR. Comparison of endotracheal, caudal thoracic air sac and clavicular air sac administration of isoflurane in sulphur-crested cockatoos (*Cacatua galerita*). *J Avian Med Surg* 2001;15(3):170-177.
41. Powell FL. Respiration. In: Whittow GC, ed. *Sturkie's Avian Physiology*. 5th ed. San Diego: Academic Press; 2000:233-264.

CE TEST

This article qualifies for 2 contact hours of continuing education credit from the Auburn University College of Veterinary Medicine. ***Subscribers may take individual CE tests or sign up for our annual CE program.*** *Those who wish to apply this credit to fulfill state relicensure requirements should consult their respective state authorities regarding the applicability of this program. CE subscribers can take CE tests online and get real-time scores at* ***CompendiumVet.com****.*

1. Uncuffed endotracheal tubes are used in avian anesthesia because

a. they have less dead space than comparably sized cuffed tubes.
b. it is easier to intubate birds with uncuffed tubes.
c. it is easier to find appropriately sized uncuffed tubes for most birds.
d. cuffed tubes, if inflated, can cause trauma to the tracheal mucosa because of complete tracheal rings.
e. none of the above

2. Ultrasound Doppler flow detectors are

a. used for monitoring heart rate and rhythm during avian anesthesia.
b. used with a sphygmomanometer to measure indirect systolic BP.
c. ineffective with inadequate gel contact between the sensor and skin.
d. ineffective when the artery is occluded by excessive pressure.
e. all of the above

3. Appropriate management for hypotension during avian anesthesia includes

a. incremental fluid boluses (100 mL/kg) until the systolic BP is greater than 90 mm Hg.
b. incremental fluid boluses (10 mL/kg) until the systolic BP is greater than 90 mm Hg.
c. doxapram administration.
d. atropine administration.
e. butorphanol administration.

4. Indications for use of an air sac cannula during avian anesthesia include

a. pneumonia or air sacculitis.
b. endoscopic evaluation and removal of a foreign body from the trachea.
c. endoscopic evaluation of air sacs.
d. surgical procedures involving the oral cavity or beak.
e. b and d

5. Which statement about air sac cannulas is false?

a. Sterile technique is not needed because the cannulated air sac will be exposed to room air.
b. The diameter of the air sac cannula should be approximately the same as that of the bird's trachea.
c. The cannula is most often placed in the caudal thoracic air sac.
d. Manual or mechanical ventilation can be administered via the air sac cannula.
e. Lack of air movement through the cannula can be due to improper positioning within the air sac.

6. Which statement regarding capnographic monitoring during avian anesthesia is true?

a. The $ETCO_2$ should be maintained below 25 mm Hg.
b. The $ETCO_2$ should be maintained above 45 mm Hg.
c. Respiratory acidosis can occur when the $ETCO_2$ is less than 50 mm Hg.
d. Respiratory alkalosis can occur when the $ETCO_2$ is more than 50 mm Hg.
e. Even birds that are breathing spontaneously can become hypercapnic.

7. Which statement regarding pulse oximeter monitoring during avian anesthesia is true?

a. A bird that is well oxygenated during anesthesia is being adequately ventilated.
b. The presence of air sacs can interfere with oxygen saturation levels recorded during anesthesia.
c. Pulse oximetry is less effective than capnography for monitoring ventilation during avian anesthesia.
d. Motion artifacts during surgery do not interfere with pulse oximetry.
e. Pulse oximeters have a tendency to overestimate values at low oxygen saturation levels.

8. If apnea occurs during avian anesthesia, the veterinarian should

a. immediately turn the anesthetic vaporizer to zero and abandon the procedure.
b. intubate the patient and start manual or mechanical ventilation.
c. check the heart rate because the heart will stop just before apnea develops.
d. place an emergency air sac cannula.
e. administer atropine and bolus fluid therapy.

9. Body temperature is most effectively maintained during avian anesthesia by

a. placement of the patient on a circulating hot water blanket.
b. placement of the patient on an insulated surface.
c. use of a heated forced-air system.
d. use of warmed intravenous fluid therapy.
e. use of warmed anesthetic gases.

10. Core body temperature monitoring is important during avian anesthesia because

a. feather plucking (i.e., loss of insulation) before surgery can lead to heat loss.
b. a large surface area relative to small body size results in rapid heat loss in birds.
c. birds can develop hypothermia even when supplemental heat is provided.
d. hypothermia can lead to prolonged recovery from anesthesia or death.
e. all of the above