

# Compendium

## Idiopathic Chylothorax in Dogs and Cats: Nonsurgical and Surgical Management

**Ameet Singh, DVM, DVSc, DACVS**  
**Brigitte Brisson, DMV, DVSc, DACVS**  
**Stephanie Nykamp, DVM, DACVR**  
University of Guelph  
Guelph, Ontario  
Canada

**Abstract:** Idiopathic chylothorax is a debilitating disease that can lead to respiratory and metabolic compromise and fibrosing pleuritis. Several treatment options are available once a diagnosis has been made. Although large-scale studies on the outcome of treatment for idiopathic chylothorax are lacking, long-term resolution of clinical signs is possible. Pathophysiology, diagnosis, and thoracic duct imaging are discussed in a companion article. This article provides an overview of nonsurgical and surgical management techniques for idiopathic chylothorax in dogs and cats.

**For more information, please see the companion article, “Idiopathic Chylothorax: Pathophysiology, Diagnosis, and Thoracic Duct Imaging”**

Evidence-based recommendations for optimal treatment of idiopathic chylothorax in dogs and cats are lacking from the veterinary literature. This is because idiopathic chylothorax is a rare disease, making randomized, prospective clinical trials of treatment strategies difficult to undertake.

### Nonsurgical Treatment

Nonsurgical treatment of chylothorax can include pleural evacuation, dietary modifications, and various drug therapies or nutritional supplements. Reported outcomes of nonsurgical treatment for idiopathic chylothorax are summarized in **TABLE 1**.

Initial therapy for dogs and cats diagnosed with chylothorax involves pleural evacuation with intermittent thoracocentesis or, if necessary, an indwelling thoracostomy tube.<sup>1</sup> Pleural evacuation is performed to temporarily alleviate respiratory compromise, improve patient comfort, and obtain samples for diagnostic evaluation. Pleural evacuation alone does not address the underlying cause of idiopathic chylothorax in dogs and cats; therefore, it is unlikely to resolve the condition.<sup>2,3</sup>

Low-fat diets have been recommended for veterinary patients with idiopathic chylothorax on the principle that such diets would reduce the volume of chyle flow through the thoracic duct (TD), which could allow spontaneous healing of TD defects.<sup>1</sup> To supplement low-fat diets, medium-chain triglyceride oil has been used because it was believed to bypass the intestinal lymphatic chain and be absorbed directly into the portal vein.<sup>1,4</sup> Results of

an experimental study in normal dogs revealed that administering a low-fat diet did indeed reduce the lipid content of TD chyle; however, it did not reduce the volume of TD lymph flow.<sup>4</sup> In the same study, contrary to prior beliefs, it was shown that medium-chain triglycerides appear to be absorbed by the intestinal lacteals in dogs and not by the portal vein.<sup>4</sup> Based on these results, low-fat diets and supplemental medium-chain triglyceride oil are not recommended for the management of canine idiopathic chylothorax. Evaluation of these dietary modifications on chyle flow in the feline TD has not been performed.

Octreotide, a somatostatin analogue, is reported to treat chylous effusion by decreasing TD flow.<sup>1,5,6</sup> Although it has been used successfully in treating humans with traumatic chylothorax, octreotide administration had variable success in five animals treated for idiopathic chylothorax.<sup>1,5,6</sup> Examination of the effects of this drug in a larger series of patients is required to determine efficacy.<sup>5</sup> Overall, the use of dietary modification and octreotide has not been shown to reduce TD flow or resolve idiopathic chylothorax in dogs and cats as in humans.<sup>1,4-6</sup> This is likely related to

**Table 1. Summary of Outcomes in Veterinary Patients Treated Nonsurgically for Idiopathic Chylothorax**

Procedure	Success Rate	References
Pleural evacuation	26%	2
Octreotide	40%	5
Rutin	67% (cats)	7-9

**Table 2. Summary of Outcomes in Veterinary Patients Treated Surgically for Idiopathic Chylothorax**

Procedure	Success Rate	References
TD ligation alone	Dogs: 50%–59% Cats: 14.3%–53%	1, 2, 13, 18–21
TD ligation + SP	Dogs: 60%–100% Cats: 80%	22, 24, 29
Thoroscopic TD ligation + pericardial window and vertical fenestrations	85.7% (dogs)	11
TD ligation + CCA	83%–87.5% (dogs)	15, 23, 29
TD ligation + SP + thoracic omentalization	72.7% <sup>25</sup> (dogs; free of clinical signs at 1825 days) 57% <sup>26</sup> (dogs and cats; free of clinical signs at 730 days) MST: 209 days (range, 2–1328), cats; 211 days (range, 7–991), dogs <sup>27</sup>	25–27

MST: median survival time

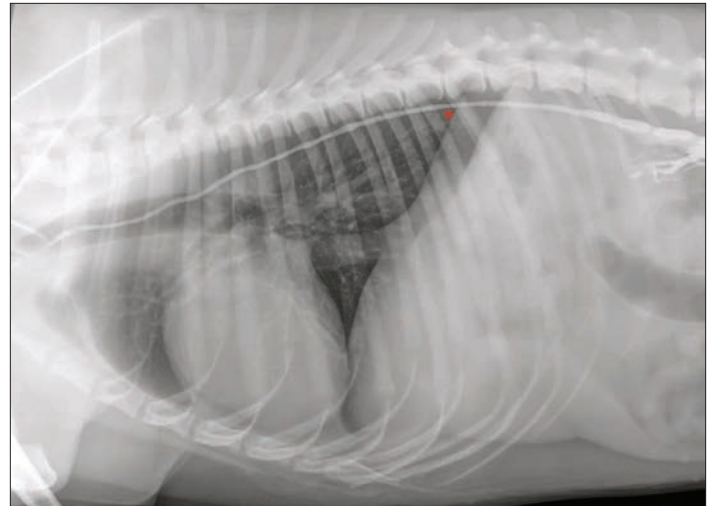
differences in the etiology (traumatic versus idiopathic) of chylothorax.

Pharmaceutical treatment of idiopathic chylothorax with furosemide or corticosteroids has been described anecdotally, but scientific evidence demonstrating the benefit of these drugs in these patients is lacking.<sup>1</sup>

Rutin, a benzopyrone derived from the Brazilian fava d'anta tree, is commonly used adjunctively in the nonsurgical management of idiopathic chylothorax.<sup>1,7–9</sup> Rutin is available over-the-counter as a nutritional supplement and has not been associated with any adverse effects in veterinary patients.<sup>1</sup> The exact mechanism by which rutin may help resolve chylothorax is unknown; however, several theories have been proposed. They include increasing the uptake of edema fluid by lymphatic vessels, reducing blood vessel permeability, and increasing tissue macrophage activity and number, thereby promoting phagocytosis of protein in edema fluid.<sup>1,7–9</sup> In three published reports,<sup>7–9</sup> a total of six cats were administered rutin in an attempt to relieve idiopathic chylothorax; five cats showed a clear improvement in clinical signs over the course of 2 to 4 weeks. There are no reports on the outcome of using rutin as the single agent to relieve idiopathic chylothorax in dogs. Although rutin has shown some promise as an adjunctive treatment in veterinary patients with idiopathic chylothorax, a randomized, double-blind prospective trial is required to determine its clinical efficacy.

### Surgical Treatment

Due to the content of chyle, chronic chylothorax can result in hypoproteinemia, immunodeficiency, dehydration, and weight loss.<sup>1</sup> Furthermore, chyle is an irritant, and chronic exposure of



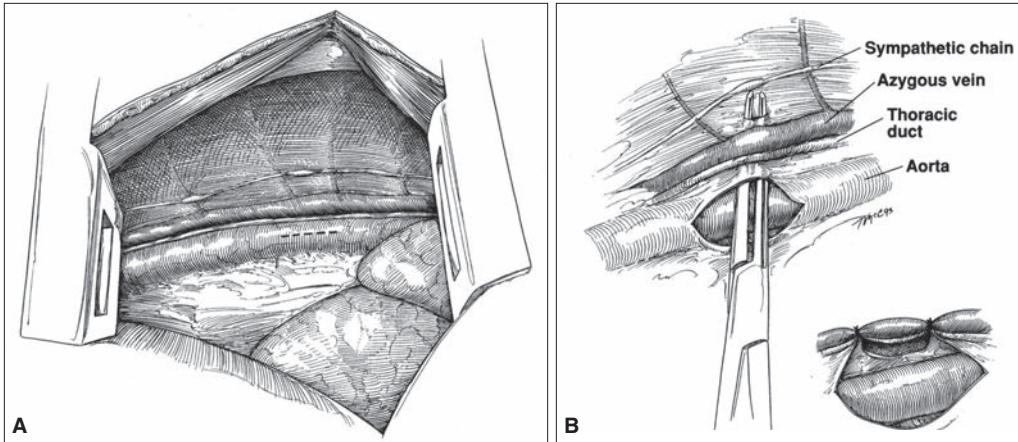
**Figure 1.** Lateral thoracic radiograph following positive contrast lymphangiography in a healthy dog. The asterisk marks the ideal location for thoracic duct ligation at its entry point into the thoracic cavity. Ligation can be achieved via a ninth or 10th intercostal thoracotomy (right side, dogs; left side, cats), median sternotomy, or minimally invasive thoracoscopy.

the pleural space to chyle can lead to life-threatening pleuritis and pericarditis.<sup>10</sup> In an effort to prevent these deleterious consequences, Allman et al<sup>11</sup> recommend surgical intervention in dogs with idiopathic chylothorax when a high-output effusion persists for more than 4 weeks despite conservative therapy. Surgical treatment also has the potential to completely resolve chylous effusion. Reported outcomes of surgical treatment for idiopathic chylothorax are summarized in **TABLE 2**.

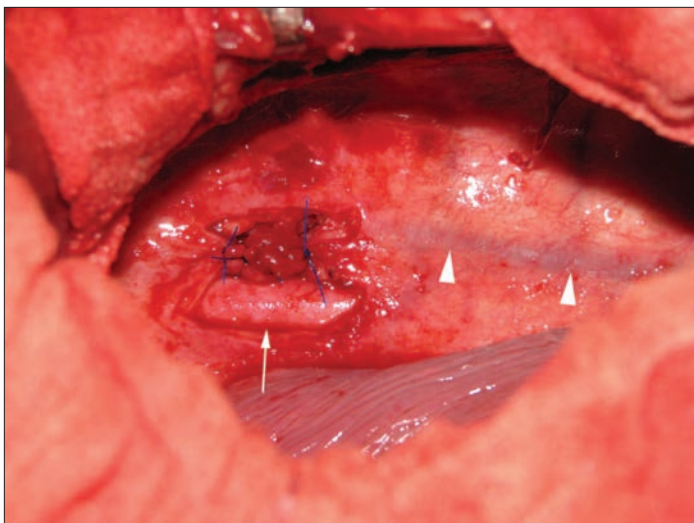
### Thoracic Duct Ligation

Patterson first described TD ligation in 1958 for treatment of traumatic chylothorax in a dog.<sup>12</sup> Since that time, TD ligation via intercostal thoracotomy has become the most commonly performed surgical technique for the treatment of idiopathic chylothorax in small animals. The goal of TD ligation is to occlude the duct at its entry point into the thorax, thereby creating a stimulus for new extrapleural lymphaticovenous connections to form (**FIGURE 1**). These new connections allow chyle to bypass the TD, preventing intrathoracic chyle flow and subsequent leak into the pleural space.

The surgical approach for TD ligation can be via a ninth intercostal thoracotomy, median sternotomy, or paracostal or ventral midline celiotomy with transdiaphragmatic extension or, for vascular clip application, via minimally invasive thoracoscopy.<sup>1,11,13–15</sup> In dogs, the TD originates on the right dorsal border of the abdominal aorta and ventral border of the azygous vein and runs cranially to the level of the sixth thoracic vertebra, where it diverges to the left side of the mediastinum. From there, it runs cranially to the level of the jugulocaval angle, where it empties its contents. An anatomic study in cats showed that the TD was predominantly on the left of midline in the caudal part of the thorax in 92% of specimens.<sup>16</sup> These anatomic differences are of key importance for veterinary surgeons and dictate the side of surgical approach



**Figure 2.** Schematic diagram describing en bloc thoracic duct ligation. In (A), after a ninth or 10th intercostal thoracotomy (right side, dogs; left side, cats), an incision is created in the mediastinal pleura to expose the thoracic aorta. In (B), after blunt dissection dorsal to the aorta and ventral to the sympathetic chain, ligatures encircle all tissues between these dissection planes. Reprinted with permission from Orton EC. Pleural effusion. In: *Small Animal Thoracic Surgery*. Philadelphia, PA: Lippincott, Williams and Wilkins; 1995:102.



**Figure 3.** Intraoperative photo of a dog undergoing surgical treatment for chronic idiopathic chylothorax. A caudal intercostal thoracotomy has been performed. The aorta (arrow) and azygous vein (arrowheads) are indicated, and three ligatures have been used to encircle all tissues dorsal to the aorta and ventral to the thoracic vertebrae and sympathetic trunk (not visible due to mediastinal thickening from chronic chylothorax).

when a paracostal or caudal intercostal thoracotomy is used for TD ligation in dogs compared with cats.

TD ligation can be performed by identification and suture ligation of, or vascular clip application to, each branch of the TD or by en bloc ligation or clipping of all structures in the caudal mediastinal tissues dorsal to the aorta and ventral to the thoracic vertebrae/sympathetic chain<sup>1,11,13-15,17</sup> (FIGURE 2 and FIGURE 3). With en bloc ligation, visualization of the TD or its branches is not attempted, which significantly reduces operative time and alleviates the need for preoperative TD imaging.<sup>13,17</sup> (For more information on TD imaging, see the companion article.)

Birchard et al<sup>18</sup> performed TD ligation via caudal intercostal thoracotomy in 12 normal dogs and three dogs with idiopathic chylothorax. Based on the results of this study, they concluded that TD ligation can successfully create alternate lymphatic pathways for chyle to return to the venous system without passing through the TD (preventing chyle leak into the pleural space) in dogs with idiopathic chylothorax.<sup>18</sup> Failure of resolution of chylous effusion was believed to be due to TD branches being missed at the time of surgery.<sup>18</sup> This finding emphasizes the importance of postoperative TD imaging to determine complete occlusion of all TD branches.<sup>18</sup>

The same authors later published the results of two separate case series in which TD ligation and pre- and postoperative TD imaging were performed in dogs with confirmed idiopathic chylothorax.<sup>1,19</sup> The reported success rates were 53% and 59%.<sup>1,19</sup> The remaining patients continued to produce a chylous or nonchylous effusion.

A cadaveric study in dogs revealed that en bloc TD ligation led to the occlusion of all TD branches in 93% of specimens.<sup>17</sup> However, in another study of en bloc TD ligation in clinical patients with idiopathic chylothorax,<sup>13</sup> only 50% of patients had successful resolution of effusion. Proponents of en bloc TD ligation argue that this technique has success rates similar to those of traditional techniques in resolving idiopathic chylothorax, without the technical demands of identifying each TD branch and the increased operative time and morbidity associated with TD imaging.<sup>13,17</sup>

In cats, the success rate of TD ligation alone ranges from 14.3% to 53%.<sup>2,20,21</sup> The higher success rate in one study<sup>21</sup> was attributed to the use of postoperative TD imaging in all cases to ensure occlusion of all branches.

### Alternative/Adjunctive Surgical Procedures Cisterna Chyli Ablation

TD ligation has been combined with several other surgical procedures in an attempt to improve success rates for the resolution of idiopathic chylothorax.<sup>22-27</sup> Sicard et al<sup>28</sup> hypothesized that the high failure rate reported for TD ligation alone resulted from the development of hypertension within the cisterna chyli and secondary collateral lymphatic vessels developing around the ligation site. The effect of TD ligation and cisterna chyli ablation (CCA) on the development of alternate lymphaticovenous connections in the abdomen was evaluated in an experimental study in research dogs.<sup>28</sup> Results of this study showed that CCA combined with TD ligation was successful in creating alternate lymphaticovenous connections in healthy dogs.<sup>28</sup> CCA can be performed via

a paracostal or ventral midline celiotomy.<sup>15,23,29</sup> When CCA and TD ligation were performed together for treatment of dogs with naturally occurring idiopathic chylothorax, an 83% to 87.5% success rate for resolution was reported.<sup>15,23,29</sup>

### Subtotal Pericardectomy

The association between diseases that lead to right-sided venous pressure elevation and chylothorax has been previously established.

(For more information on disease association, see the companion article.) Fossum et al<sup>22</sup> hypothesized that the development of a thickened pericardium secondary to chylothorax may lead to increased right-sided venous pressure that could in turn impede chyle drainage through new lymphaticovenous connections formed as a result of TD ligation. For this reason, TD ligation and subtotal pericardectomy (SP) have been advocated for treating idiopathic chylothorax.<sup>22</sup> Fossum et al reported resolution of chylous effusion in 100% of dogs (10 of 10) and 80% of cats (8 of 10) after TD ligation with SP in 17 animals and SP alone in 3 animals.<sup>22</sup> These success rates for resolution of chylous effusion using the combination of TD ligation and SP have been corroborated in several recent studies.<sup>24–27,29</sup>

Although use of the combination of TD ligation and SP has not been reported for large numbers of animals, the reported success rates in resolving idiopathic chylothorax in dogs and cats are much improved compared with the 53% (in cats) and 59% (in dogs) success rates with TD ligation alone.<sup>1,2,18–22,24–27,29</sup> Despite the fact that elevated right-sided venous pressures have not been documented

in any case of naturally occurring idiopathic chylothorax,<sup>29</sup> combining SP with TD ligation is considered the current surgical standard of care for veterinary patients with idiopathic chylothorax.

### Thoracic Omentalization

Two single case reports in a dog<sup>30</sup> and a cat<sup>31</sup> describe the use of omental advancement through an incision in the pars costalis of the diaphragm for the treatment of idiopathic chylothorax with long-term resolution of clinical signs. In both cases, extensive pleural fibrosis prevented TD ligation at the time of thoracotomy. The omentum has a large absorptive surface area that can provide lymphatic drainage and has been used in a variety of veterinary surgical procedures in an attempt to take advantage of its beneficial properties.<sup>32</sup> Thoracic omentalization alone for the treatment of idiopathic chylothorax has been questioned because omental lymph flow eventually drains into the TD.<sup>30</sup> Omentalization has also been performed in combination with TD ligation and SP.<sup>25–27</sup> The utility of thoracic omentalization requires further investigation before it can be definitively recommended in combination with TD ligation and SP.

### Pleurodesis

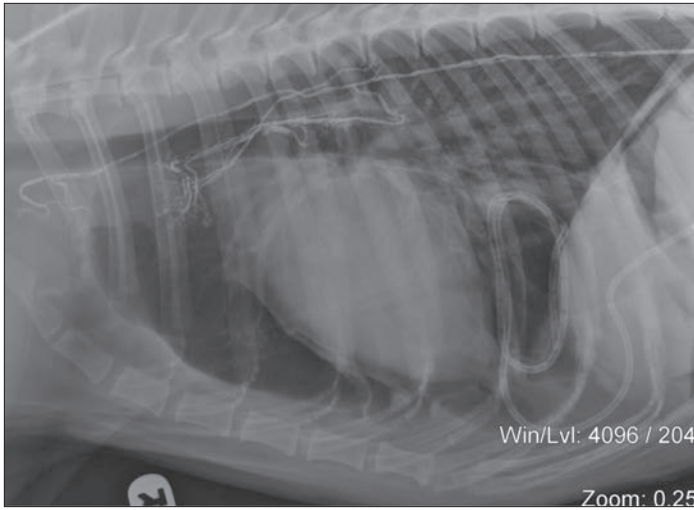
Pleurodesis is the creation of adhesions between the parietal and visceral pleurae, which effectively abolishes the pleural space.<sup>33</sup> It has been used in veterinary patients to treat spontaneous pneumothorax and chronic pleural effusions, including idiopathic chylothorax.<sup>34,35</sup> Pleurodesis can be attempted chemically by the instillation of talc or tetracycline into the pleural space to create an inflammatory response and induce adhesion formation.<sup>33–35</sup> Mechanical abrasion of the parietal and visceral pleurae has also been performed to attempt pleurodesis in dogs.<sup>33</sup> Tetracycline pleurodesis was attempted in dogs with naturally occurring idiopathic chylothorax.<sup>35</sup> A 50% resolution rate of chylothorax was achieved; however, complications were common and included pleural pain, fever, hypoproteinemia, and weight loss.<sup>35</sup> Experimental studies have failed to show effective and complete pleurodesis in dogs (regardless of technique) and, based on the complications seen in clinical cases, this method of treating idiopathic chylothorax has been abandoned.<sup>33–35</sup>

### Cisterna Chyli and Thoracic Duct Embolization

Embolization of the cisterna chyli and TD has been described as a technique to eliminate forward flow of chyle into the TD.<sup>36,37</sup> Cyanoacrylate glue is injected through a cannulated mesenteric lymphatic vessel; the glue is mixed with radiographic contrast so that embolization can be guided using fluoroscopy<sup>37</sup> (FIGURE 4). This technique eliminates the morbidity associated with thoracotomy and achieved complete TD occlusion in 100% (8 of 8) of healthy dogs in one study.<sup>36</sup> When this technique was performed in dogs with naturally occurring idiopathic chylothorax, resolution occurred in only 33% (2 of 6) cases.<sup>38</sup> Weisse et al<sup>37</sup> have reported the use of this technique as a salvage procedure in patients with idiopathic chylothorax if previous surgical techniques have failed.

### Key Points

- Conservative therapy can be attempted initially in dogs or cats with idiopathic chylothorax; however, spontaneous resolution is unlikely and surgical intervention is frequently performed.
- Thoracic duct (TD) ligation is the most commonly performed surgical technique for the treatment of idiopathic chylothorax. It can be performed via a caudal intercostal thoracotomy, paracostal or ventral midline celiotomy with transdiaphragmatic extension, or median sternotomy or using minimally invasive thoracoscopy.
- Adjunctive procedures in addition to (or without) TD ligation have been used to improve success rates. These include subtotal pericardectomy, cisterna chyli ablation, and thoracic omentalization.
- The most common complication related to surgical intervention is persistence of pleural effusion, which can be chylous or nonchylous in nature.
- In cases of idiopathic chylothorax in which surgical treatment has failed, implantation of an active pleuro-peritoneal shunt or PleuralPort can be considered. The pleuroperitoneal shunt requires manual compression of the pump chamber several times daily by the owner to actively transfer chyle from the pleural to peritoneal space. The PleuralPort requires the owner to aspirate the hub of the device, which is implanted in subcutaneous tissue, to evacuate the pleural fluid.



**Figure 4.** Lateral thoracic radiograph of a dog that has undergone cysterna chyli and thoracic duct embolization using a mixture of cyanoacrylate glue and radiographic contrast agent. The glue mixture is visible within the thoracic duct and branches. (Courtesy of Dr. Chick Weisse)

### Minimally Invasive Techniques

Traditional surgical techniques for treatment of idiopathic chylothorax in veterinary patients are invasive (intercostal thoracotomy for TD ligation with or without second intercostal thoracotomy for SP and laparotomy for mesenteric lymphangiography) and require the patient to be under general anesthesia for prolonged periods.

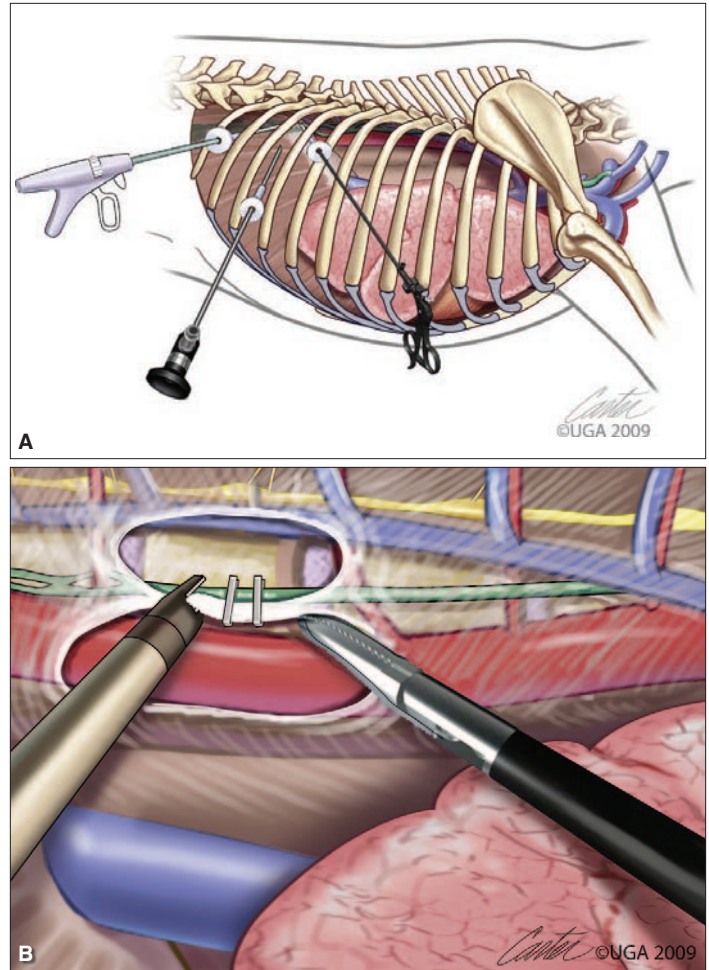
Video-assisted thoracoscopic surgery (VATS) for TD ligation is a minimally invasive approach for the treatment of idiopathic chylothorax in veterinary patients.<sup>11</sup> Thoracoscopic surgery provides excellent visualization and illumination of the thoracic cavity without the morbidity of an open thoracotomy.<sup>11</sup>

A recent study described the use of VATS for the treatment of chylothorax in 12 dogs, in seven of which the chylothorax was deemed idiopathic.<sup>11</sup> VATS was used to apply vascular clips to branches of the TD or in an en bloc fashion<sup>11</sup> (FIGURES 5A and 5B). The patients were then repositioned in dorsal recumbency, and a thoracoscopic SP was performed.<sup>11</sup> The success rate achieved for resolution of idiopathic chylothorax (85.7%) was similar to rates previously reported for TD ligation and SP with open thoracotomy.<sup>11,22,24–27,29</sup>

Thoracoscopic CCA was successfully performed in an experimental study in dogs but has not yet been reported in combination with TD ligation and SP for treatment of clinical cases of idiopathic chylothorax.<sup>39</sup> These three surgical procedures (TD ligation, SP, and CCA) could be performed in a minimally invasive fashion to optimize the chance of resolving idiopathic chylothorax. However, prospective clinical studies are required to substantiate this approach.

### Complications of Thoracic Duct Ligation

The most common complication of TD ligation is the postoperative persistence of pleural effusion, which can be chylous or nonchylous in nature.<sup>1,19</sup> Persistent effusion has been reported in up to 40% of cases even after lymphangiographic confirmation that all TD



**Figure 5.** Schematic diagram (A) showing the endoscope and instrument port sites for minimally invasive thoracic duct ligation in a dog. Close-up schematic view (B) of minimally invasive thoracic duct ligation. The dissection is between the intercostal arteries. The aorta is retracted ventrally, and clips have been applied to all tissue within the dissected mediastinal segment. (Art by Kip Carter. © 2010 University of Georgia Research Foundation, Inc.) Reprinted with permission from Tams TR, Rawlings CA. Thoracoscopy. In: Small Animal Endoscopy. 3rd ed. St. Louis, MO: Mosby; 2011:494.

branches were ligated at the time of surgery.<sup>19</sup> Possible explanations for persistent chylous effusion include failure to occlude all branches of the TD at the time of surgery; opening of small, non-patent TD branches after TD ligation; and development of collateral lymphatic vessels around the ductal ligation site.<sup>18,19,23</sup> Although not commonly discussed in the veterinary literature, the postoperative time required for chylous effusion to resolve can vary. In our clinical experience, resolution has occurred anywhere from 1 to 50 days after successful TD ligation and SP. Why the time period for resolution of chylothorax varies has yet to be determined.

Nonchylous effusion was reported to accumulate after TD ligation in 33% of dogs in one study.<sup>19</sup> Although there was no clear explanation for this effusion, cytologic examination of this fluid was consistent with chronic inflammation.<sup>19</sup> It has also been theorized that lymphangiectasia and leakage of lymph from

inflamed pulmonary lymphatic vessels that do not communicate with the TD may lead to nonchylous effusion after TD ligation.<sup>19,40</sup>

Kerpsack et al<sup>41</sup> were the first to report the development of collateral TD branches around the site of ductal ligation in a dog. They suggested that delayed, recurrent chylous effusion after TD ligation was the result of collateral lymphatic vessel formation around the ligation site rather than failure to ligate all the existing branches at the time of surgery.<sup>41</sup> They also theorized that even though postoperative mesenteric lymphangiography verified occlusion of all TD branches, ligation of the main TD and major collaterals had resulted in the increase of intraluminal pressure within small, nonpatent collateral branches that distended and became patent over time.<sup>41</sup>

The accumulation of chyle in fluctuant masses in the subcutaneous tissues of the inguinal region and hindlimb was reported in a dog with idiopathic chylothorax secondary to TD ligation.<sup>42</sup> Fluid aspirated from these tissues was consistent with chyle, yet thoracic radiography revealed minimal pleural effusion.<sup>42</sup> Although a rare complication of TD ligation, it appears that some dogs may not develop alternate pathways for chyle drainage into the venous system after TD ligation.<sup>42</sup>

### Long-Term Outcomes of Surgical Treatment

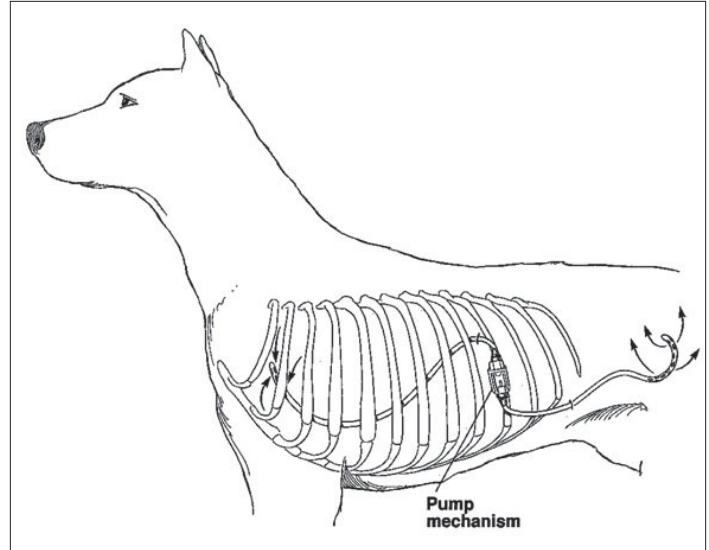
Few studies have evaluated the long-term outcome of veterinary patients undergoing surgical treatment of idiopathic chylothorax. Recurrence of chylous effusion more than 5 years after surgical intervention has been reported.<sup>1</sup> The underlying mechanism of delayed recurrence is unknown. A recent study<sup>25</sup> reported that 73% (8 of 11) dogs that had undergone surgical treatment (TD ligation with SP and thoracic omentalization) for idiopathic chylothorax were free of clinical signs 5 years postoperatively. Although the number of cases was low, this study provides evidence for owners of animals with idiopathic chylothorax that long-term resolution of chylous effusion is possible.<sup>25</sup>

### Surgical Techniques Used for Refractory Cases

Several implantable devices have been used for palliative evacuation of the pleural space in patients with idiopathic chylothorax that does not resolve after attempted TD ligation or for which definitive surgical therapy was declined.<sup>37-44</sup> While intermittent thoracocentesis or thoracostomy tube implantation have been used for long-term pleural evacuation, these approaches require frequent veterinary attention and/or prolonged hospitalization. Furthermore, they are associated with several risks, including infection, iatrogenic pulmonary injury, and accidental removal by the animal. An ideal device would be one that is manageable at home by the owners, does not lead to discomfort after implantation, is not easily removed by the animal, and can be placed in a minimally invasive fashion.

### Pleuroperitoneal/Pleurovenous Shunts

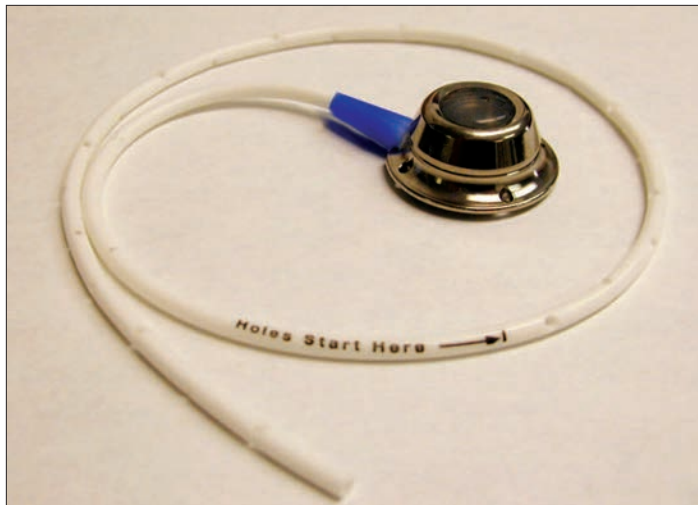Active and passive pleuroperitoneal devices shunt chyle from the pleural to peritoneal space to alleviate respiratory compromise and improve patient comfort by relying on the absorptive capacity of the peritoneal surface.<sup>43-50</sup> Active shunts rely on negative



**Figure 6.** Schematic diagram showing positioning of a Denver double-valve pleuroperitoneal shunt in a dog. When the pump mechanism is compressed, fluid is expelled from the chamber into the peritoneal cavity through the efferent catheter. After release of the pump mechanism, the chamber expands, pulling fluid from the pleural cavity into the afferent catheter and refilling the chamber for subsequent compressions. Reprinted with permission from EC Orton. *Pleural effusion.* In: *Small Animal Thoracic Surgery.* Philadelphia, PA: Lippincott, Williams and Wilkins; 1995: 92.

pressure; passive shunts require gravity for fluid movement. The most commonly used device in veterinary patients is the active pleuroperitoneal Denver shunt, which was developed as a peritoneal-venous shunt for use in humans with intractable ascites<sup>44</sup> (FIGURE 6). The Denver shunt is too large to be implanted in cats; a pediatric version of this shunt has been used in this species.<sup>45</sup> Once the pump is implanted, the owner must manually compress the pump chamber (placed in the subcutaneous tissues) several times daily to generate the negative pressure necessary to shunt fluid.

The largest report on the use of active pleuroperitoneal shunts for chronic pleural effusion included 14 dogs, 10 of which had idiopathic chylothorax.<sup>44</sup> TD ligation had failed to resolve chylous effusion in nine of 10 dogs with idiopathic chylothorax, and one dog with chylothorax was deemed a poor candidate for TD ligation based on the presence of cranial and caudal mediastinal lymphangiectasia.<sup>44</sup> The median time between TD ligation and implantation of a pleuroperitoneal shunt was 15 days.<sup>44</sup> This time frame was based on recommendations from the human literature.<sup>44</sup> An overall mean survival time of 27 months and a disease-free interval (free of clinical signs from pleural effusion) of 20 months were reported.<sup>44</sup> Both short- (53.8%) and long-term (72.7%) complications were reported and included tube obstruction, infection, pump chamber dislodgment from the thorax, marked abdominal distention, pyothorax, peritonitis, and owner compliance problems.<sup>44</sup> Despite the high complication rate, most owners were satisfied with outcomes and did not mind the need for manual pump chamber compression numerous times daily.<sup>44</sup> The authors stated that pleuroperitoneal shunting may fail in some cases as a result of



**Figure 7.** The PleuralPort device consists of a titanium hub that is surgically placed in the subcutaneous tissues overlying the thorax and is attached to a radiopaque fenestrated drainage tube, which is inserted into the thorax in a minimally invasive fashion.

abdominal distention (chyloperitoneum) if the absorptive capacity of the peritoneum is overwhelmed or if the shunt cannot maintain adequate drainage of the pleural space in cases of high-output chylothorax.<sup>44</sup>

Passive pleuroperitoneal shunts have been used in treating two cats and a single dog diagnosed with idiopathic chylothorax.<sup>46,47</sup> Palliation of clinical signs related to chylothorax was successful in all three patients in which this technique was performed.<sup>46,47</sup> In one study,<sup>47</sup> a surgically created defect in the diaphragm was replaced with a fenestrated Silastic sheet. Implant obstruction by the liver and omentum likely impair drainage with long-term maintenance of these devices.<sup>1</sup>

The Denver shunt has been applied as a pleurovenous shunt in four dogs in two reports.<sup>48,49</sup> Of these four dogs, two had spontaneous

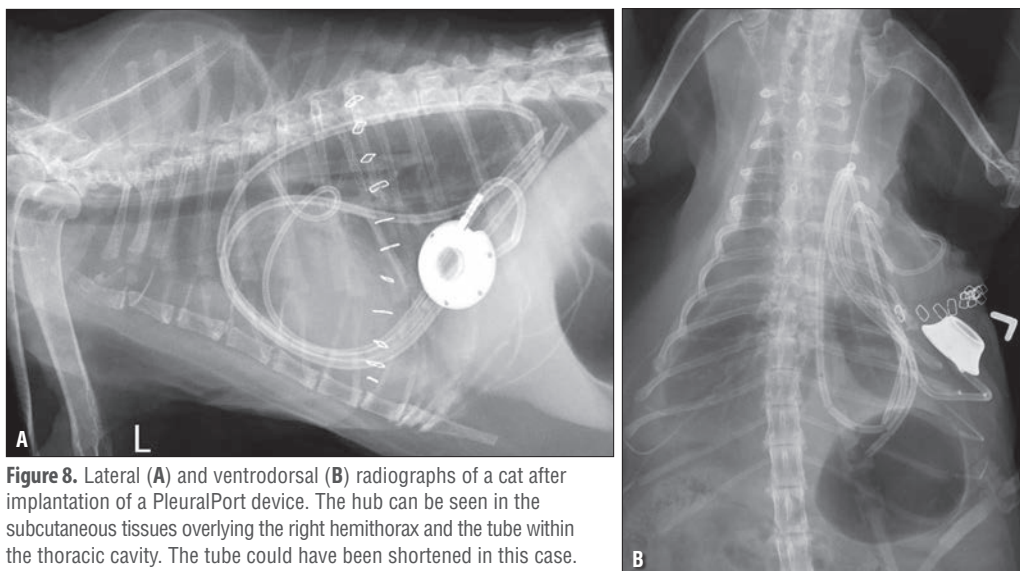
resolution of chylous effusion and the other two were euthanized because of complications from the pleurovenous shunt.<sup>48,49</sup> Concerns relating to thrombosis and technical difficulty have precluded the widespread use of this technique.

### PleuralPort

This device may be ideally suited for the management of refractory idiopathic chylothorax in small animals. The PleuralPort (Norfolk Vet Products, Skokie, IL) consists of a titanium hub that is attached to a radiopaque, fenestrated, 10-Fr drainage tube (**FIGURE 7**). The hub is surgically placed in the subcutaneous tissues overlying the thorax, and the drainage tube is inserted into the thorax in a minimally invasive fashion<sup>50</sup> (**FIGURES 8A** and **8B**). The hub can be aspirated using a noncoring Huber point needle, which allows for multiple punctures without damaging the hub septum.<sup>50</sup> Once the device is implanted, owners can evacuate the pleural space at home by aspirating the hub of the PleuralPort after aseptic preparation of the overlying skin. A recent case series has reported the successful use of this device for palliative management of intractable pleural effusion in small animals.<sup>50</sup>

### Conclusion

Conservative treatment of idiopathic chylothorax in dogs and cats is rarely successful, and surgical intervention is often required. With the addition of adjunctive procedures to TD ligation, much higher success rates have been reported for the resolution of idiopathic chylothorax compared with those for TD ligation alone. Minimally invasive thoracoscopy for TD ligation and SP has shown great promise with success rates similar to those for open techniques and should be performed if the equipment and skill are available. Thoracoscopic CCA has been described in an experimental setting and may eventually be combined with TD ligation and SP in clinical cases of idiopathic chylothorax to maximize the chance of resolution. Surgical management of this devastating disease can provide long-term relief of clinical signs.



**Figure 8.** Lateral (A) and ventrodorsal (B) radiographs of a cat after implantation of a PleuralPort device. The hub can be seen in the subcutaneous tissues overlying the right hemithorax and the tube within the thoracic cavity. The tube could have been shortened in this case.

### References

1. Birchard SJ, Smeak DD, McLoughlin MA. Treatment of idiopathic chylothorax in dogs and cats. 1998;212:652-657.
2. Harpster NK. Chylothorax. In: Kirk RW, ed. Philadelphia: WB Saunders; 1986:295-303.
3. Blalock A, Cunningham RS, Robinson CS. Experimental production of chylothorax by occlusion of the superior vena cava. 1936;104:359-363.
4. Sikkema DA, McLoughlin MA, Birchard SJ. Effect of dietary fat on triglyceride and fatty acid composition of thoracic duct lymph in dogs. 1993;22:398-399.
5. Sicard GK, Hardie RJ, Hayashi K, et al. The use of somatostatin analogue (octreotide) for the treatment of idiopathic chylothorax in dogs and cats. 2003;32:496.
6. Fernandez Alvarez JR, Kalache KD, Grauel EL. Management of spontaneous congenital chylothorax: oral medium-chain triglycerides

versus total parenteral nutrition. 1999;16:415-420.

7. Thompson MS, Cohn LA, Jordon RC. Use of rutin for medical management of idiopathic chylothorax in four cats. 1999;215:345-348.
8. Gould L. The medical management of idiopathic chylothorax in a domestic long-haired cat. 2004;45:51-54.
9. Kopko SH. The use of rutin in a cat with idiopathic chylothorax. 2005;46:729-731.
10. Fossum TW, Evering WN, Miller MW, et al. Severe bilateral fibrosing pleuritis associated with chronic chylothorax in five cats and two dogs. 1992;201:317-324.
11. Allman DA, Radlinsky MG, Ralph AG, et al. Thoracoscopic thoracic duct ligation and thoracoscopic pericardectomy for treatment of chylothorax in dogs. 2010;39:21-27.
12. Patterson DF, Munson TO. Traumatic chylothorax in small animals treated by ligation of the thoracic duct. 1958;133:452-458.
13. Viehoff FW, Stokhof AA. En bloc ligation of the thoracic duct in twelve dogs with idiopathic chylothorax. 2003;128:278-283.
14. Martin RA, Leighton D, Richards S, et al. Transdiaphragmatic approach to thoracic duct ligation in the cat. 1988;17:22-26.
15. Staiger BA, Stanley BJ, McAnulty JF. Single paracostal approach to the thoracic duct and cisterna chyli: experimental study and case series. 2011;40:786-794.
16. Lindsay FEF. Chylothorax in the domestic cat—a review. 1974;15:241-258.
17. MacDonald NJ, Noble PJ, Burrow RD. Efficacy of en bloc ligation of the thoracic duct: descriptive study in 14 dogs. 2008;37:696-701.
18. Birchard SJ, Cantwell HD, Bright RM. Lymphangiography and ligation of the canine thoracic duct: a study in normal dogs and three dogs with chylothorax. 1982;18:769-777.
19. Birchard SJ, Smeak DD, Fossum TW. Results of thoracic duct ligation in dogs with chylothorax. 1988;193:68-71.
20. Fossum TW, Forrester SD, Swenson CL, et al. Chylothorax in cats: 37 cases (1969-1989). 1991;198:672-678.
21. Kerssack SJ, McLoughlin MA, Birchard SJ, et al. Evaluation of mesenteric lymphangiography and thoracic duct ligation in cats with chylothorax: 19 cases (1987-1992). 1994;205:711-715.
22. Fossum TW, Mertens MM, Miller MW, et al. Thoracic duct ligation and pericardectomy for treatment of idiopathic chylothorax. 2004;18:307-310.
23. Hayashi K, Sicard G, Gellasch K, et al. Cisterna chyli ablation with thoracic duct ligation for chylothorax: results in eight dogs. 2005;34:519-523.
24. Carobbi B, White RA, Romanelli G. Treatment of idiopathic chylothorax in 14 dogs by ligation of the thoracic duct and partial pericardectomy. 2008;163:743-745.
25. da Silva CA, Monnet E. Long-term outcome of dogs treated surgically for idiopathic chylothorax: 11 cases (1995-2009). 2011;239:107-113.
26. Bussadori R, Provera A, Martano M, et al. Pleural omentalization with en bloc ligation of the thoracic duct and pericardectomy for idiopathic chylothorax in nine dogs and four cats. 2010;188:234-236.
27. Stewart K, Padgett S. Chylothorax treated via thoracic duct ligation and omentalization. 2010;46:312-317.
28. Sicard GK, Waller KR, McAnulty JF. The effect of cisterna chyli ablation combined with thoracic duct ligation on abdominal lymphatic drainage. 2005;34:64-70.
29. McAnulty JF. Prospective comparison of cisterna chyli ablation to pericardectomy for treatment of spontaneously occurring idiopathic chylothorax in the dog. 2011;40:926-934.
30. Williams JM, Niles JD. Use of omentum as a physiologic drain for treatment of chylothorax in a dog. 1999;28:61-65.
31. Lafond E, Weirich WE, Salisbury SK. Omentalization of the thorax for treatment of idiopathic chylothorax with constrictive pleuritis in a cat. 2002;38:74-78.
32. Hosgood G. The omentum—the forgotten organ; physiology and potential surgical applications in dogs and cats. 1990;112:45-51.
33. Jerram RM, Fossum TW, Berridge BR, et al. The efficacy of mechanical abrasion and talc slurry as methods of pleurodesis in normal dogs. 1999;28:322-332.
34. Gallagher LA, Birchard SJ, Weisbrode SE. Effects of tetracycline hydrochloride on pleurae in dogs with induced pleural effusion. 1990;51:1682-1687.
35. Orsher RJ, Harvey CE. Tetracycline sclerotherapy (pleurodesis) for the treatment of chylothorax in a dog. 1990;72-73.
36. Pardo AD, Bright RM, Walker MA, et al. Transcatheter thoracic duct embolization in the dog. An experimental study. 1989;18:279-285.
37. Weisse CW, Berent AC, Todd KL, et al. Potential applications of interventional radiology in veterinary medicine. 2008;233:1564-1574.
38. Pardo AD. Thoracic duct embolization for the treatment of chylothorax. 1995;552-554.
39. Sakals S, Schmiedt CW, Radlinsky MG. Comparison and description of transdiaphragmatic and abdominal minimally invasive cisterna chyli ablation in dogs. 2011;40:795-801.
40. Bilbrey SA, Birchard SJ. Pulmonary lymphatics in dogs with experimentally induced chylothorax. 1994;30:86-91.
41. Kerssack SJ, Smeak DD, Birchard SJ. Progressive lymphangiectasis and recurrent chylothorax in a dog after thoracic duct ligation. 1995;207:1059-1062.
42. Farnsworth R, Birchard S. Subcutaneous accumulation of chyle after thoracic duct ligation in a dog. 1996;208:2016-2019.
43. Smeak DD, Gallagher L, Birchard SJ, et al. Management of intractable pleural effusion in a dog with pleuroperitoneal shunt. 1987;16:212-216.
44. Smeak DD, Birchard SJ, McLoughlin MA, et al. Treatment of chronic pleural effusion with pleuroperitoneal shunts in dogs: 14 cases (1985-1999). 2001;219:1590-1597.
45. Donner GS. Use of the pleuroperitoneal shunt for the management of persistent chylothorax in a cat. 1989;25:619-622.
46. Capcorn TM, Read RA. Successful treatment of chylothorax in a dog by passive pleuroperitoneal drainage. 1995;25:186-194.
47. Peterson SL, Pion PD, Breznock EM. Passive pleuroperitoneal drainage for management of chylothorax in two cats. 1989;25:569-572.
48. Willauer CC, Breznock EM. Pleurovenous shunting technique for treatment of chylothorax in three dogs. 1987;191:1106-1109.
49. Peterson SL. Postcaval thrombosis and delayed shunt migration after pleuro-peritoneal venous shunting for concurrent chylothorax and chylous ascites in a dog. 1996;25:228-230.
50. Brooks AC, Hardie RJ. Use of the PleuralPort™ device for management of pleural effusion in six dogs and four cats. 2011;40:935-941.





3 CE Credits

This article qualifies for 3 contact hours of continuing education credit from the Auburn University College of Veterinary Medicine. CE tests must be taken online at [Vetlearn.com](http://Vetlearn.com); test results and CE certificates are available immediately. Those who wish to apply this credit to fulfill state relicensure requirements should consult their respective state authorities regarding the applicability of this program.

**1. Which statement is false regarding conservative treatment for idiopathic chylothorax?**

- a. It rarely leads to spontaneous resolution.
- b. It improves patient comfort and respiratory compromise.
- c. Dietary modification and octreotide can be successfully used for resolution of idiopathic chylothorax in most cases.
- d. Rutin, an over-the-counter nutraceutical, has been used successfully in the treatment of idiopathic chylothorax in cats.

**2. Reducing dietary fat results in**

- a. reduced fat in chyle.
- b. reduced flow of chyle through the TD.
- c. resolution of idiopathic chylous effusion.
- d. selective uptake of medium-chain triglycerides.

**3. Which is the goal of TD ligation?**

- a. to create a stimulus for the formation of extrapleural lymphaticovenous connections
- b. to create a stimulus for the formation of intrapleural lymphaticovenous connections
- c. to reduce TD chyle flow to allow spontaneous healing
- d. all of the above

**4. Which statement regarding TD ligation is true?**

- a. When combined with pericardectomy or CCA, TD ligation has a higher success rate.
- b. TD ligation is typically more successful in cats than dogs.
- c. Minimally invasive thoracoscopic TD ligation is not as effective as open techniques.
- d. En bloc TD ligation is associated with longer operative times compared with other surgical procedures.

**5. One potential reason that TD ligation does not provide long-term resolution of idiopathic chylothorax in all cases is**

- a. leakage of chyle caudal to the ligation site.
- b. impaired lymphatic drainage from the pleural surface.
- c. iatrogenic damage to the TD at the time of surgery.
- d. development of collateral lymphatic vessels around the ligation site.

**6. Which statement is false regarding CCA?**

- a. When combined with TD ligation, it resulted in improved success rates in resolving idiopathic chylothorax in a small number of dogs compared with TD ligation alone.
- b. It is thought to reduce the stimulus for collateral lymphatic vessel formation around the TD ligation site.
- c. It has been shown to be successful in resolving idiopathic chylothorax when performed by itself.
- d. It can be performed via a paracostal or ventral midline celiotomy.

**7. When used for the treatment of idiopathic chylothorax, minimally invasive surgical techniques do not**

- a. reduce the morbidity associated with thoracotomy incisions.
- b. improve postoperative resolution rates.
- c. allow TD ligation and SP.
- d. provide excellent visualization and illumination.

**8. Thoracic omentalization in combination with TD ligation and SP may be an effective adjunctive treatment for idiopathic chylothorax because**

- a. the omentum provides a large surface area to absorb the chyle.
- b. the lymphatic drainage of the omentum bypasses the TD.
- c. thoracic omentalization can lead to reduced central venous pressure.
- d. the presence of omentum in the thorax stimulates fibrosis and pleurodesis.

**9. Which statement about pleuroperitoneal shunts is true?**

- a. They are commonly used as an initial treatment for chylothorax.
- b. Passive shunts may become obstructed by the liver or omentum.
- c. Active shunts have a low complication rate.
- d. Ascites (chyloperitoneum) never occurs because of the absorptive capacity of the omentum.

**10. Which statement regarding the PleuralPort is true?**

- a. It cannot be implanted in cats.
- b. It cannot be placed in a minimally invasive fashion.
- c. It shunts fluid from the pleural to the peritoneal space.
- d. It requires the owner to aspirate a subcutaneously located hub for pleural fluid removal.