

Diaphragmatic Hernia: Treatment, Complications, and Prognosis*

Gal Kelmer, DVM, MS, DACVS^a

Joanne Kramer, DVM, DACVS

David A. Wilson, DVM, MS, DACVS

University of Missouri-Columbia

ABSTRACT: Diaphragmatic hernia in horses presents a challenge to the surgeon and the anesthetist. Surgical repair is the treatment of choice, and success rates have improved considerably in the past few decades. When the condition has been diagnosed, thoracoscopy is helpful in localizing the lesion and deciding on the best surgical approach. Lateral rib-resection thoracotomy is advantageous for accessing common, deep-dorsal diaphragmatic hernia lesions. Anesthetic considerations play a major role in the outcome and include fine-tuned, controlled mechanical ventilation and close monitoring of arterial blood gases. Early diagnosis, versatility in surgical approaches, proper surgical and anesthetic techniques, and aggressive postoperative management allow a successful outcome.

Surgical repair of diaphragmatic hernia (herniorrhaphy) in horses poses anesthetic and surgical challenges that have contributed to the poor prognosis generally associated with this condition.¹⁻⁷ For example, severe bilateral pneumothorax and ventilation inadequacy may cause life-threatening problems in the immediate postoperative period. These complications can be avoided or successfully managed with a well-planned surgery and intensive postoperative care and monitoring. As evidenced by several reports

describing successful surgical treatment of diaphragmatic hernia in horses,⁸⁻²² the success rate for surgical management of this condition has improved. One reason for this improvement is the use of special surgical approaches that provide better access to lesions that are not readily accessible via a routine ventral midline approach. Furthermore, lateral thoracoscopy-assisted thoracotomy may improve access to lesions that commonly affect the dorsal aspect of the diaphragm, thereby improving the surgical success rate. Thus although diaphragmatic hernia repair is a challenging procedure in the horse, with improved methods of diagnosis, new surgical approaches, and intensive postoperative care and monitoring, it need not carry the poor prognosis frequently mentioned in the literature.^{2,4,6,23-25}

*A companion article on etiology, clinical presentation, and diagnosis of diaphragmatic hernia begins on page 28.

^aDr. Kelmer is now affiliated with the University of Tennessee College of Veterinary Medicine.

- Take CE tests
- See full-text articles



CompendiumEquine.com

EXPLORATORY CELIOTOMY

Rarely is the diagnosis of diaphragmatic hernia made preoperatively. In most cases, affected horses present for evaluation of acute abdominal pain and the diagnosis is made during exploratory celiotomy.^{9,10,14,17,20,26–29} In several cases described in the literature, the defect was inaccessible, giving the surgeon four options: (1) euthanize the horse on the table, (2) reposition the horse to make the lesion more accessible, (3) recover the horse and attempt to repair the lesion using a different approach, or (4) recover the horse without repairing the diaphragmatic defect. Three horses did well in the long term and engaged in athletic activity without closure of the defect.^{10,15,28} In two of the horses, there was no direct communication between the abdomen and the thoracic cavities; one horse had a pleuropericardial hernia and the other a retrosternal (Morgagni) hernia.^b These types of diaphragmatic hernia reduce the likelihood of intraoperative and postoperative complications.¹⁵

CONSERVATIVE MANAGEMENT

As with other diseases that require surgical intervention, there are reports of conservative management of diaphragmatic hernia. For example, in one report,³⁰ a horse with diaphragmatic hernia involving the large colon remained comfortable at pasture for 2 years but was unable to exercise due to dyspnea and had occasional bouts of abdominal discomfort. Eventually, the horse was euthanized due to severe colic. We recently encountered a similar situation with a mare that presented with acute colic and responded well to aggressive medical management. Although diaphragmatic hernia involving the large colon was diagnosed, surgery was not an option. The mare was comfortable at pasture for 2 months and was then euthanized due to severe colic. Given the outcome in these two cases, we recommend surgery even in horses in which clinical signs have resolved.

SURGICAL MANAGEMENT

Surgical intervention is the treatment of choice to remove the abdominal viscera from the thorax, repair the diaphragmatic defect, and, when indicated, perform intestinal resection and anastomosis.⁷ In some cases, the diaphragmatic defect is repaired at a later date, often using a different surgical approach.

^bThe different types of equine abdominal hernia are described in the companion article starting on page 28.

Timing of Surgical Repair

Delayed (4 to 12 weeks) hernia repair in horses is advocated for incisional and traumatic body-wall hernias.³¹ The goal of delaying the repair is to allow fibrous tissue to form at the margins of the defect. Compared with frayed, friable, fresh hernial borders, mature hernial borders increase the likelihood that sutures will hold the tissue in position. For the same reason, it may be advantageous to delay repair of large, fresh diaphragmatic lesions.^{12,13,32,33} However, it has been reported that intestine may become incarcerated in the thoracic cavity during recovery from anesthesia when the defect is not repaired at the time of diagnosis.^{9c}

In certain patients, such as a horse with a large, fresh defect that is not showing significant clinical signs, delaying the repair may be justified. In such cases, the horse can be monitored closely for several weeks and then undergo surgical repair.³² Ideally, the preoperative waiting period should be spent at a surgical facility, enabling immediate intervention if necessary. In contrast, small diaphragmatic defects, even if fresh, should be closed immediately due to the high risk for repeat small intestinal incarceration.⁹ If surgical time for the initial exploratory celiotomy is prolonged and the patient is unstable under anesthesia, planning thoracotomy for hernia repair the next day may be the best course of action.^d

Surgical Approaches

Several surgical approaches have been used for diaphragmatic hernia repair,^{10,13,21,26,34} with many authors advocating a cranioventral midline approach to provide adequate visualization of and accessibility to the lesion.^{4,8,10,19,27} In foals, the cranioventral midline approach can provide adequate access to all aspects of the diaphragm. However, in adult horses, this approach provides excellent access to the central ventral aspect of the diaphragm but very limited access to the dorsal diaphragm. Slightly more than one-third (41 of 114) of diaphragmatic hernia cases involved only the ventral aspect of the diaphragm.^c Thus, a cranioventral midline celiotomy provides very limited access to and visibility of most (>60%) diaphragmatic hernias in horses.

Several manipulations can improve the surgeon's access to a lesion when a cranioventral midline approach is

^cFarnsworth K. Personal communication, Washington State University, College of Veterinary Medicine, Pullman, WA, 2005.

^dFischer Jr AT. Personal communication, Chino Valley Equine Hospital, Chino, CA, 2005.

^eThe distribution of diaphragmatic defects is described in the companion article starting on page 28.

AN IN-DEPTH LOOK

used. Tilting the surgery table into a reverse Trendelenburg position (head up 30°) facilitates caudal displacement of the viscera, thus improving visibility of the diaphragm, especially its dorsal aspect.³⁴ In addition, tilting the table laterad away from the affected side may provide better access to a diaphragmatic defect.^{20,22} Extending the cranioventral midline incision 15 to 20 cm laterad and parallel to the last rib at the level of the xiphoid process can increase accessibility to dorsal diaphragmatic defects. This approach requires incising the abdominal muscles and can result in significant intraoperative hemorrhage.³⁴ Exteriorizing the ascending and descending colon onto a colon tray may also improve accessibility to the diaphragm.²⁸

A flank approach can be used to localize the lesion by manual palpation, and the results of this surgery can be used to determine how best to approach the lesion via thoracotomy.¹³ An alternative approach involves thoracoscopy, a technique that provides excellent visibility of the diaphragm in standing and laterally recumbent horses.^{21,35} Thoracoscopy has proven to be safe in healthy horses and in diagnosing and treating thoracic lesions.^{21,36} Although the fenestrated mediastinum of the horse makes bilateral pneumothorax a concern when thoracoscopy is used,^{35,37} experience indicates that the contralateral lung usually remains inflated during thoracoscopic procedures.^{21,35} In theory, standing thoracoscopy may be used to close a small dorsal diaphragmatic defect diagnosed during exploratory celiotomy. Although thoracoscopy is the preferred technique for diaphragmatic hernia repair in human patients,^{38,39} successful diaphragmatic mesh repair using a thoracoscopic approach has not been reported in horses.

A lateral thoracotomy via rib resection is recommended for use in cattle with diaphragmatic hernia,^{32,40,41} and this approach provides good access to dorsal diaphragmatic defects in horses.^{13,21,32} After the defect has been localized by abdominal exploration, palpation through a flank incision, laparoscopy, or thoracoscopy, the approach is made directly over the lesion. Lateral thoracotomy was used in the first reported description of diaphragmatic hernia repair in a horse²⁶ as well as in two subsequent cases.^{13,21} Because more than 60% of all diaphragmatic defects in horses are located dorsally, a lateral thoracotomy would be suitable in most cases.^{42,c} In certain cases, an additional small incision may be needed to allow an assistant's hand to be inserted into the thorax to aid in suturing the defect.^d

Key Points

- Conservative management of equine diaphragmatic hernia commonly results in recurrence. Surgical repair is the treatment of choice.
- Successful repair of diaphragmatic hernia can result in a return to full reproductive and athletic potential.
- Although ventral midline celiotomy is the most commonly reported and recommended approach for diaphragmatic hernia repair, it does not provide the visibility and accessibility crucial for successful repair of common dorsal diaphragmatic defects.
- Lateral rib-resection thoracotomy provides direct access to common dorsal diaphragmatic defects. Thoracoscopy facilitates identification and removal of the correct rib.
- According to the literature, diaphragmatic hernia repair carries a guarded to poor prognosis; however, a more favorable prognosis can be achieved with early diagnosis, a lateral thoracotomy approach, and intensive perioperative care.

Reduction of Herniated Viscera

The first step in surgical correction of a diaphragmatic hernia is reduction of the herniated abdominal contents, which may be simple in some cases and challenging in others.^{12,13,19,22,43} Difficulties are often encountered when the large colon is involved.^{13,22,43} Tilting the surgery table head up and laterad (away from the lesion) can be invaluable in facilitating reduction.^{20,34} Massaging the herniated intestinal loops and advancing their contents into the abdomen reduces the weight of the involved intestine and decreases the chances of tearing the intestinal wall.¹⁸ Sections of large colon that are incarcerated in the thorax and distended with gas should be decompressed through the diaphragm before an attempt is made to return them to the abdomen.¹³ In many cases, the diaphragmatic defect must be enlarged to achieve reduction without excessively compressing and damaging the incarcerated intestine.^{10,11,17,20,29} To reduce the likelihood of intestinal damage, the defect should be extended cautiously, using a palm-protected scalpel blade, a guarded fetotome, a bistoury knife, or scissors.^{10,11,14,34} Care must be taken to avoid incising the phrenic vessels, which can result in fatal hemorrhage.

After the herniated viscera have been returned to the abdomen, they should be evaluated for viability. When the large colon is involved (Figure 1), it is usually viable due to the nonstrangulating nature of the lesion.^{8,12,20} However, one report described a horse with a strangulated large colon that required resection and anastomosis.

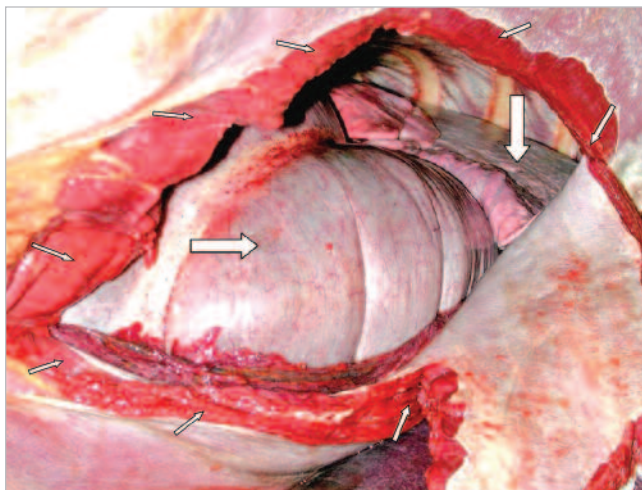


Figure 1. Postmortem photograph of an acquired diaphragmatic hernia in a 10-year-old quarter horse mare. The fresh margins of the tear in the diaphragm (small arrows) and the ascending colon (horizontal arrow) can be seen within the thoracic cavity adjacent to the lungs (vertical arrow).

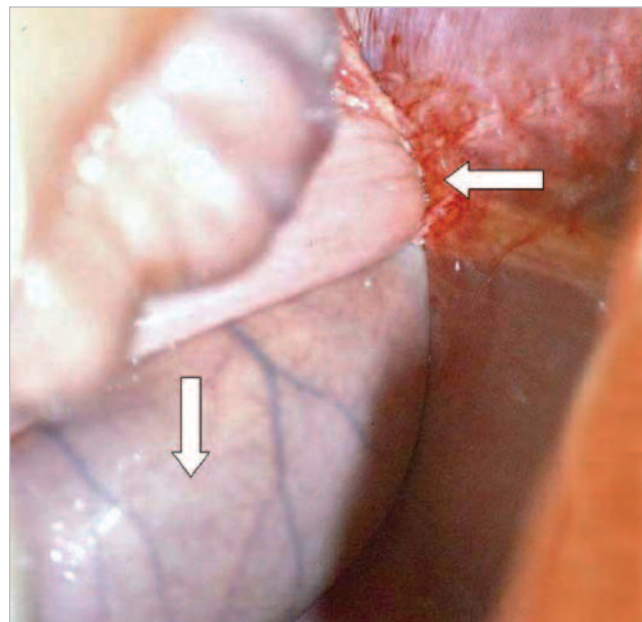


Figure 2. Postmortem photograph showing small intestine (vertical arrow) strangulated in a small diaphragmatic defect (horizontal arrow).

Photo by John C. Janicek, DVM, DACVS

sis.¹⁴ When the small intestine is incarcerated in the thorax (Figure 2), it is typically strangulated, nonviable, and in need of resection and anastomosis.^{7,10,17} If abdominal repair of the diaphragmatic defect is planned, it should be performed before intestinal resection and anastomosis.¹⁷ Closing the diaphragmatic defect is often challenging and may be the most difficult part of surgery; thus this procedure should be performed before investing time and effort in intestinal surgery.³⁴

Hernia Repair

Hernia closure should always begin in the most inaccessible area, typically the most dorsal aspect of the lesion, and advance toward the most accessible region. Several techniques have been reported for repairing the damaged diaphragm,^{8,9,12-14,16-18,22,44,45} some of which include freshening of the hernia ring before closure to facilitate healing.^{13,20} Diaphragmatic defects have been closed directly using heavy (no. 1 or no. 2), synthetic absorbable or nonabsorbable suture material (e.g., polydioxanone, polyglactin 910, prolene) in a variety of suture patterns, including simple interrupted, horizontal, or vertical mattress.^{10,13,19,20,22,44} Other defects have been repaired using a simple, continuous pattern augmented with simple, interrupted sutures or divided into several sections.^{8,12,14,17}

Several techniques are reported to facilitate direct suturing of defects and securing mesh in regions to

which access is limited, such as the dorsal diaphragm. These techniques include starting the knot extracorporeally and sliding it down, preplacing the sutures, using a loop suture to avoid the first knot, using double-armed suture for preplacement, and using long-handled instruments or staplers.^{13,14,16,18,28,d} If closure of the defect proves to be difficult, omentum, peritoneum, or transverse abdominus muscle can be used.^{19,20}

Large, friable, less accessible, or less pliable diaphragmatic defects can be closed with synthetic mesh (e.g., Marlex [C.R. Bard, Murray Hill, NJ]),^{9,16,18,45,46} Because the mesh may contact intestine, use of either bioabsorbable mesh (e.g., Surgisis [Cook Medical, Bloomington, IN]) or laminated mesh with a bioabsorbable layer (e.g., Proceed [Ethicon, Piscataway, NJ]) on the exposed side may be advantageous. If the mesh is placed against the abdominal side of the defect, the viscera will press it against the diaphragm and retain it in place. Because application of mesh does not resolve the pneumothorax created by communication of the thoracic and abdominal cavities, omentum or a muscle flap can be used to cover the mesh to hasten airtight sealing of the diaphragmatic defect.^{4,33} Placing a 28- to 32-Fr polyvinyl chloride chest tube before recovery from anesthesia is generally indicated,^{4,33,34} especially when an airtight diaphragmatic seal has not been achieved because mesh was used or the

AN IN-DEPTH LOOK

defect at the xiphoid region was not completely closed.^{9,18,20} The chest tube is also necessary when pleural effusion exists or is expected postoperatively.^{8,20,47}

In humans, congenital diaphragmatic hernia containing a hernial sac, or *diaphragmatic eventration*, has been repaired by plication. Plication involves suturing the diaphragm into folds to decrease its surface area. This procedure tightens the diaphragm without excising or incising it and avoids the use of mesh and its inherent risks. Plication may prove to be useful in treatment of true diaphragmatic hernia, such as retrosternal (Morgagni) hernia, or diverticulum, which are uncommon in horses.^{16,28,37}

ANESTHETIC CONSIDERATIONS

Rapid systemic deterioration, impairment of ventilation, or development of hypoxemia after induction, positioning in dorsal recumbency, or opening the abdominal cavity in a horse anesthetized for emergency abdominal surgery should alert the anesthetist to the possibility of diaphragmatic hernia.⁴⁸

Anesthesia of a horse with a diaphragmatic hernia is challenging. The difficulty of the procedure is directly related to the volume of viscera in the thorax. Because the caudal mediastinum is often fenestrated in horses,^{37,49} returning the herniated intestine to the abdomen may cause bilateral pneumothorax and aggravate the already compromised respiratory function.^{29,37,49} Respiratory insufficiency, manifested by hypoxemia and hypercarbia, develops rapidly, and frequent intraoperative arterial blood gas monitoring is critical to evaluate ventilation efficacy and adequacy of oxygenation.^{48,50,51} If a complete hernial sac is present, as in cases of Morgagni diaphragmatic hernia, the horse should require far less respiratory support because the respiratory system is only minimally affected.^{16,28}

The anesthetist may also find it difficult to maintain an adequate plane of anesthesia,⁵⁰ and anesthesia-related mortality is common among reported cases of attempted diaphragmatic hernia repair.^{29,32,50,51} Diaphragmatic hernia poses two anesthetic problems: hypoventilation and decreased oxygenation. Hypoventilation is a result of lung compression by the abdominal viscera and the loss of thoracic negative pressure required for lung inflation. Oxygenation decreases due to alveolar collapse in the atelectatic lung.⁵² Consequently, mechanical ventilation and the use of 100% oxygen are essential during anesthesia for repair of diaphragmatic hernia.^{29,53} In a recent report⁵² of anesthesia for correction of a diaphragmatic hernia involving the large colon, ventilation proved dif-

ficult even with a controlled mechanical ventilator. Ventilation and oxygenation improved only after the large colon was removed from the thorax. Other authors have reported that it is difficult to maintain horses with diaphragmatic hernia under an adequate plane of anesthesia.⁵⁰ Some affected horses deteriorate rapidly preoperatively or stop breathing after induction of anesthesia or transition to dorsal recumbency. These changes are most likely caused by increased pressure on the lungs by the viscera.^{32,54} Some horses deteriorate rapidly after the abdominal cavity is opened, with the most common findings being severe hypoxemia, hypercapnia, changes in mucosal color, and increases in blood pressure.⁵⁰ Decreased intraoperative lung compliance is demonstrated by an increase in the circuit pressure required for proper ventilation.⁵⁰ Providing 100% oxygen at 10 to 15 L/min through tracheal or nasal insufflation before and after surgery may be beneficial in horses with diaphragmatic hernia. Chronically collapsed lungs should be reinflated cautiously, with awareness of the potential complications of emphysema and pulmonary edema.^{20,55} Anesthesia for horses with diaphragmatic hernias is not without risk and potential hazards, but with preoperative stabilization, careful monitoring, and judicious intraoperative and postoperative support, it can yield a positive outcome.

INTRAOPERATIVE COMPLICATIONS

Failure to diagnose diaphragmatic hernia during exploratory celiotomy has been reported and can lead to the patient's demise either in surgery or shortly afterward.^{25,48} Fatal intraoperative complications include failure to return the viscera to the abdominal cavity, irreparable intestinal lesions, irreparable diaphragmatic defects, and difficulty in maintaining adequate ventilation and oxygenation.^{25,27,43,47,51} Complications commonly related to gastrointestinal surgery, such as adhesions and postoperative ileus, may occur. Although adhesions of the defect to herniated viscera are uncommon, omental and liver adhesions have been reported; adhesiolysis in such cases may result in fatal hemorrhage or intestinal rupture.^{20,30,56} Because the equine mediastinum is often fenestrated, bilateral pneumothorax may occur intraoperatively as the viscera are returned to the abdominal cavity.^{32,35,37,49,57}

POSTOPERATIVE CARE

Postoperative care must address both abdominal and thoracic cavities. Initial care should include oxygen sup-

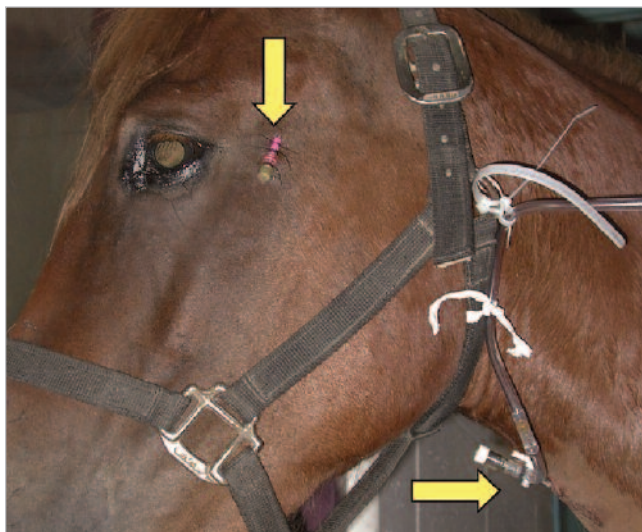


Figure 3. Photograph of a 4-year-old mare after repair of a penetrating thoracic injury. The mare has an intratracheal catheter (horizontal arrow) for administration of 100% oxygen and an intraarterial catheter in the facial artery (vertical arrow) for intermittent postoperative arterial blood gas monitoring.

plementation, broad-spectrum parenteral antimicrobial therapy, analgesics, and intravenous fluid therapy. Oxygen (100%; 10 to 15 L/min) should be administered either by intranasal intubation or via an intratracheal catheter (Figure 3). When a thoracic approach is used, or when the horse has sustained thoracic trauma, proper pain management should be instituted.^{57,58} The use of opioids (e.g., butorphanol), either in repeated boluses or as a continuous-rate infusion, may be especially helpful in the early postoperative period.⁵⁸ Although horses with diaphragmatic hernia have been treated successfully without a chest tube, an indwelling chest tube is recommended in the early (12- to 72-hr) postoperative period.^{9,14,17,18,22,57-59} If a chest tube is not inserted during surgery, it can be placed immediately after recovery. A unidirectional valve (Heimlich) should be connected to the chest tube after the horse is standing to prevent damage to the valve during recovery. When significant volumes of air or fluid are expected, continuous suction using a commercial three-chamber suction system (e.g., Thora-Seal [Sherwood Medical Company, St. Louis, MO]) is an efficient method of evacuating the thoracic cavity (Figure 4). Arterial blood gas monitoring in the early postoperative period may prove useful in monitoring ventilation and oxygenation and is especially indicated if the respiratory effort is increased. Serial postoperative thoracic radiographs are indicated to

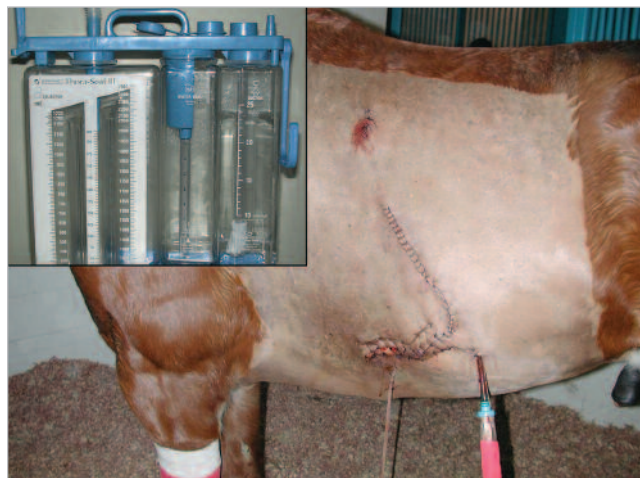


Figure 4. Photograph of a 7-year-old quarter horse gelding presented with a penetrating thoracoabdominal injury resulting in a diaphragmatic hernia. This photograph was taken 2 days after repair of the diaphragmatic hernia and wound exploration and repair using lateral thoracotomy. A secured rigid thoracic drain with a Heimlich valve is in place caudal to the sutured wound. The inset shows a commercial three-bottle continuous suction system to drain air and fluid from the thorax (Thora-Seal).

assess resolution of pneumothorax (Figure 5) and hemothorax. Mild pneumothorax may be left to be absorbed gradually with no untoward effects.^{53,55}

POSTOPERATIVE COMPLICATIONS

Postoperative complications include dehiscence of the diaphragmatic defect repair and additional tearing of the diaphragm, both of which can be fatal.^{20,45} In humans and small animals, reexpansion pulmonary edema may result from rapid lung inflation after prolonged collapse. In these species, survival rates after diaphragmatic hernia repair were improved by gradual rather than rapid air evacuation.^{58,60} To date, clinical and experimental experience suggests that rapid lung inflation does not lead to clinically significant side effects in the horse, regardless of the duration of pulmonary collapse.^{36,49,57} Some authors suggest judiciously inflating the lungs just before sealing the diaphragm to avoid alveoli rupture; these authors advocate evacuating the air from the thoracic cavity gradually using an indwelling thoracic tube.²⁰ Some degree of pneumothorax and pleural effusion is to be expected after thoracic surgery.^{8,14} Both of these complications can be prevented by proper drainage through an indwelling chest tube. If, however, these complications are not addressed in a

AN IN-DEPTH LOOK

timely fashion, either may prove to be fatal.^{7,13,53,59} Because the development of septic pleuritis can have a fatal outcome,⁶¹ broad-spectrum parenteral antibiotic coverage and aseptic surgical technique are important preventive measures in affected horses.⁵⁷

A review of published cases revealed that several horses died from respiratory failure during recovery or shortly after diaphragmatic hernia repair.^{20,26,29,46} Consequently, the following are important measures: preoperative, intraoperative, and postoperative supplementation with 100% oxygen; intraoperative use of controlled mechanical ventilation; and close monitoring of ventilation and oxygenation efficacy with serial evaluation of arterial blood gases during and after surgery.

RESULTS

In reviewing the literature, we identified 53 horses with diaphragmatic hernia, including six cases of our own, that underwent abdominal surgery and had postoperative follow-up.^{5,8-23,25-29,43,45-51,62,63} More than 50% (27 of 53) of the surgeries were successful. Several horses were euthanized on the table solely due to the poor prognosis attributed to diaphragmatic hernia.^{48,51,62} Including only cases that recovered from anesthesia, the success rate was 90% (27 of 30), with a successful outcome being defined as survival to discharge from the hospital. The mean duration of hospitalization for these horses was 16 days (range: 5 to 26 days). Nearly 60% (16 of 27) of the horses with a successful outcome had large (≥ 10 cm) defects. The thoracic cavity contained only small intestine in 11 cases, only large colon in 10 cases, both small intestine and large colon in four cases, and only omentum in one case. Of the horses that had an unsuccessful outcome after surgery, 17 of 26 had large defects, and the thoracic cavity contained only small intestine in nine cases, only large colon in eight cases, both small intestine and large colon in two cases, and stomach and either spleen or liver in two cases. Thus neither the size of the defect nor the identity of the herniated contents appeared to be an important factor leading to a successful outcome. In contrast, the location of the diaphragmatic defect was unevenly distributed among the reported cases, with about 25% (seven of 27) being dorsal in the cases with a successful outcome and 61% (16 of 26) being dorsal in the cases with unsuccessful outcomes. Similarly, the chronicity of the defect was unevenly distributed among the reported cases, with less than 4% (one of 27) being fresh in the successful cases and 23% (six of 26) being fresh in the cases with an unsuccessful outcome.




Figure 5. Lateral thoracic radiograph showing unilateral pneumothorax with an indwelling thoracic drain (downward curved arrow). The collapsed lung is visible ventrally (upward curved arrow).

Most of the reports of cases with unsuccessful outcomes appeared in the literature before 1990.^{8,25,26,29,43,46-48,51,62} We reviewed 20 successful cases of surgically treated diaphragmatic hernia in horses after 1990, with an average follow-up of 20 months after discharge (range: 3 months to 5 years). These horses were capable of continuous athletic and reproductive activities, including racing, jumping, and foaling.^{9,10,13-15,17,19,20} Presumably, the advances in anesthetic and surgical techniques that have been achieved in the past 17 years were instrumental in these successful outcomes. A larger number of cases with long-term (1 year minimum) follow-up are necessary in order to draw firmer conclusions regarding the likelihood of long-term functionality of horses after diaphragmatic hernia repair.

PROGNOSIS

The prognosis for horses with diaphragmatic hernia has often been listed as poor.^{1,3-7,20,48} Unfortunately, several horses categorized as surgical failures in the literature were euthanized at surgery after diagnosis, based solely on the poor prognosis ascribed to the lesion,^{23,48,62} and other horses were euthanized after a preoperative diagnosis, based on the same assumptions.^{1-3,5} According to several recently reported cases, however, the prognosis is better than previously believed. This improvement is due to several factors, including the ability to successfully anesthetize systemically compromised patients using precise, controlled ventilation; continuous direct

blood pressure monitoring; and routine, frequent arterial blood gas evaluation. Marked improvements have also been made in gastrointestinal surgery techniques. Small intestinal resection and anastomosis, which are frequently indicated in diaphragmatic hernia cases, have a much higher survival rate than in previous years.⁶⁴ The development of thoracoscopic techniques and the use of staples have also contributed to the improved surgical success rate. Thoracic injuries without major coexisting lesions have a favorable prognosis despite the combination of fractured ribs, pneumothorax, and hemothorax.⁵⁷ According to our review of cases in the literature, lesion location and freshness can influence the outcome of repair of diaphragmatic hernia. Fresh dorsal defects carry the worst prognosis, while chronic, more ventral defects carry better chances for a successful outcome. Using thoracotomy and delaying surgery, when appropriate, may improve the prognosis and decrease the negative influence of dorsal location and recent injury. If an early diagnosis is made based on astute clinical evaluation and a well-planned surgery is performed with proper anesthetic support, repair of diaphragmatic hernia in the horse can be successful.

REFERENCES

- Everett KA, Chaffin MK, Brinsko SP. Diaphragmatic herniation as a cause of lethargy and exercise intolerance in a mare. *Cornell Vet* 1992;82:217-223.
- Ewart S, Williams A, Stickle R. What is your diagnosis? Diaphragmatic hernia in a horse. *JAVMA* 1992;201:493-494.
- Goehring LS, Goodrich LR, Murray MJ. Tachypnoea associated with a diaphragmatic tear in a horse. *Equine Vet J* 1999;31:443-445.
- Hance SR, Clem MF, DeBowes RM. Intraabdominal hernias in horses. *Compend Contin Educ Pract Vet* 1991;13:293-299.
- Hartzband LE, Kerr DV, Morris EA. Ultrasonographic diagnosis of diaphragmatic rupture in a horse. *Vet Radiol* 1990;31:42-44.
- Holt PE. Hernias and ruptures in the horse. *Equine Pract* 1986;8:13-16.
- Honnas CM. Diaphragmatic hernia. In: White NA, Moore JN, eds. *Current Practice of Equine Surgery*. Philadelphia: JB Lippincott; 1990:267-269.
- Clarke LM, Arighi M, Jamison JM. Clinical diagnosis and surgical repair of a diaphragmatic hernia in a mare. *Can Vet J* 1987;28:242-244.
- Dabareiner RM, White NA. Surgical repair of a diaphragmatic hernia in a racehorse. *JAVMA* 1999;214:1517-1518, 1496.
- Edwards GB. Diaphragmatic hernia in the horse—a diagnostic and surgical challenge. *Equine Vet Educ* 1993;5:267-269.
- Hill FW, Knottenbelt DC, van Laeren K. Repair of a diaphragmatic hernia in a horse. *Vet Rec* 1987;120:127-129.
- Levine SB, Myhre GD. Surgical repair of a traumatic diaphragmatic hernia in a horse. *Equine Pract* 1983;5:31-34.
- Malone ED, Farnsworth K, Lennox T, et al. Thoracoscopic-assisted diaphragmatic hernia repair using a thoracic rib resection. *Vet Surg* 2001;30:175-178.
- Moll HD, Wallace MA, Sysel A. Large colon strangulation due to a diaphragmatic hernia in a mare: a case report. *J Equine Vet Sci* 1999;19:58-59.
- Orsini JA, Koch C, Stewart B. Peritoneopericardial hernia in a horse. *JAVMA* 1981;179:907-910.
- Proudman CJ, Edwards GB. Diaphragmatic diverticulum (hernia) in a horse. *Equine Vet J* 1992;24:244-246.
- Santschi EM, Juzwiak JS, Moll HD, et al. Diaphragmatic hernia repair in three young horses. *Vet Surg* 1997;26:242-245.
- Scott EA, Fishback WA. Surgical repair of diaphragmatic hernia in a horse. *JAVMA* 1976;168:45-47.
- Speirs VC, Reynolds WT. Successful repair of a diaphragmatic hernia in a foal. *Equine Vet J* 1976;8:170-172.
- Steenhaut M, Verschooten F, De Moor A, et al. Surgical correction of diaphragmatic hernia in the horse: a report on 6 cases. *Vlaams Diergeneeskund Tijdschr* 1992;61:181-186.
- Vachon AM, Fischer AT. Thoracoscopy in the horse: diagnostic and therapeutic indications in 28 cases. *Equine Vet J* 1998;30:467-475.
- Verstchooten F, Oyaert W, Muylle E, et al. Diaphragmatic hernia in the horse: four case reports. *J Am Vet Radiol Soc* 1977;18:45-50.
- Bryant JE, Sanchez LC, Rameriz S, et al. What is your diagnosis? Herniation of the intestines into the caudal region of the thorax. *JAVMA* 2002;220:1461-1462.
- Collobert C, Gillet JP, Esling W. A case of congenital diaphragmatic hernia in a foal. *Equine Pract* 1988;10:43-46.
- Wimberly HC, Andrews EJ, Haschek WM. Diaphragmatic hernias in the horse: a review of the literature and an analysis of six additional cases. *JAVMA* 1977;170:1404-1407.
- Mason TA, Johnston DE, Wallace CE, et al. Laparotomy in equine colic—a report of thirteen clinical cases. *Aust Vet J* 1970;46:349-355.
- Corley J. Diaphragmatic hernia in a horse. *Equine Pract* 1990;12:28-31.
- Pauwels FF, Hawkins JF, MacHarg MA, et al. Congenital retrosternal (Morgagni) diaphragmatic hernias in three horses. *JAVMA* 2007;231:427-432.
- Pearson H, Pinsent PJ, Polley LR, et al. Rupture of the diaphragm in the horse. *Equine Vet J* 1977;9:32-36.
- Roelvink MEJ, Sloet van Oldruitenborgh-Oosterbaan MM, Calsbeek HC. Chronic diaphragmatic hernia in the horse. *Equine Vet Educ* 1993;5:255-258.
- Hardy J, Rakestraw PC. Postoperative care and complications associated with abdominal surgery. In: Auer JA, Stick JA, eds. *Equine Surgery*. Philadelphia: Saunders; 1999:302-303.
- Bristol DG. Diaphragmatic hernias in horses and cattle. *Compend Contin Educ Pract Vet* 1986;8:S407-S412.
- Kaneps AJ. Hernias. In: Auer JA, ed. *Equine Surgery*. Philadelphia: WB Saunders; 1992:415-416.
- Freeman DE. Surgery of the small intestine. *Vet Clin North Am Equine Pract* 1997;13:261-301.
- Peroni JF, Horner NT, Robinson NE, et al. Equine thoracoscopy: normal anatomy and surgical technique. *Equine Vet J* 2001;33:231-237.
- Peroni JF, Robinson NE, Stick JA, et al. Pleuropulmonary and cardiovascular consequences of thoracoscopy performed in healthy standing horses. *Equine Vet J* 2000;32:280-286.
- Rooney JR. Evisceration of the thorax, neck, and head. In: *Necropsy of the Horse: Technique and Interpretation*. Huntington, NY: Robert E. Krieger; 1976:26.
- Wadhwa A, Surendra JB, Sharma A, et al. Laparoscopic repair of diaphragmatic hernias: experience of six cases. *Asian J Surg* 2005;28:145-150.
- Wiener DC, Jaklitsch MT. Surgery of the diaphragm: a deductive approach. In: Sellke FW, del Nido PJ, Swanson SJ, eds. *Sabiston & Spencer Surgery of the Chest*. 7th ed. Philadelphia: Elsevier Saunders; 2005:506-516.
- Gaughan EM, Provo-Klimek J, Ducharme NG. Surgery of the bovine respiratory and cardiovascular systems. In: Fubini SL, Ducharme NG, eds. *Farm Animal Surgery*. St. Louis: Saunders; 2004:157.
- Singh SS, Mirakhor KK, Singh KI, et al. Standing thoracotomy and diaphragmatic herniorrhaphy in a cow. *Vet Rec* 1996;139:240.
- Speirs VC, Boulton CH. Lower respiratory system. In: Auer JA, ed. *Equine Surgery*. Philadelphia: WB Saunders; 1992:496-506.
- Wyn-Jones G, Baker JR. A probable congenital diaphragmatic defect in an adult pony. *Vet Rec* 1979;105:251-252.
- Markel MD, Kerr LY. What is your diagnosis? *JAVMA* 1987;190:1599-1600.
- Perdrizet JA, Dill SG, Hackett RP. Diaphragmatic hernia as a cause of dyspnoea in a draft horse. *Equine Vet J* 1989;21:302-304.
- Schmitz DG, Morris EL, Scrutchfield WL. Diaphragmatic hernia in a horse. *Equine Pract* 1987;9:26-29.
- Mair TS, Pearson H, Watermann AE. Chylothorax associated with congenital diaphragmatic defect in a foal. *Equine Vet J* 1988;20:304-306.

AN IN-DEPTH LOOK

48. Firth EC. Diaphragmatic hernia in horses. *Cornell Vet* 1976;66:353-361.
49. Boy MG, Sweeney CR. Pneumothorax in horses: 40 cases (1980-1997). *JAVMA* 2000;216:1955-1959.
50. Clutton RE, Boyd C, Richards DL, et al. Anesthetic problems caused by diaphragmatic hernia in the horse: a review of four cases. *Equine Vet J Suppl* 1992;(11):30-33.
51. McGrath CJ, Gordon B, Byer L. Diaphragmatic hernia in the horse. *Vet Med Small Anim Clin* 1981;76:733-737.
52. Branson KR, Kramer J. Anesthesia case of the month. Diaphragmatic hernia making it difficult to ventilate a horse during anesthesia. *JAVMA* 2000;216:1918-1919.
53. Steenhaut M, Verschooten F. Diaphragmatic hernia in the horse. *Vet Annu* 1996;36:256-263.
54. Sasse HHL, Kalsbeek HC. Hernia diaphragmatica traumatica in the horse. *Tijdschr Diergeneeskunde* 1965;90:1327-1341.
55. Wilkins P. Lower airway diseases of the adult horse. *Vet Clin North Am Equine Pract* 2003;19:101-121.
56. Soldan AW, Johnston A. Diaphragmatic hernia in a horse. *Vet Rec* 1987;120:239.
57. Laverty S, Lavoie JP, Pascoe JR. Penetrating wounds to the thorax in 15 horses. *Equine Vet J* 1996;28:220-224.
58. Worth AJ, Machon RJ. Traumatic diaphragmatic herniation: pathophysiology and management. *Compend Contin Educ Pract Vet* 2005;27:178-191.
59. Freeman DE. Small intestine. In: Auer JA, Stick JA, eds. *Equine Surgery*. Philadelphia: Saunders; 1999:246-247.
60. Mahfood S, Hix WR, Aaron BL, et al. Reexpansion pulmonary edema. *Ann Thorac Surg* 1988;45:340-345.
61. Dieckmann M, Deegan E, Klein HJ. Zwerchfellhernie bei einem 14 jährigen islandpferd. *Pferdeheilkunde* 1989;5:263-265.
62. Auer DE, Wilson RG, Groenendyk S, et al. Diaphragmatic rupture in a mare at parturition. *Equine Vet J* 1985;17:331-333.
63. Ethell MT, Haines G, Graham JP, et al. What is your diagnosis? Small intestinal obstruction as a result of incarceration in a diaphragmatic hernia. *JAVMA* 1999;215:321-322.
64. Freeman DE, Hammock P, Baker GJ, et al. Short- and long term survival and prevalence of postoperative ileus after small intestinal surgery in the horse. *Equine Vet J Suppl* 2000;32:42-51.

ARTICLE #2 CE TEST

This article qualifies for 2 contact hours of continuing education credit from the Auburn University College of Veterinary Medicine. Subscribers may purchase individual CE tests or sign up for our annual CE program. Those who wish to apply this credit to fulfill state relicensure requirements should consult their respective state authorities regarding the applicability of this program. CE subscribers can take CE tests online and get real-time scores at CompendiumEquine.com.

1. Which statement regarding conservative management of diaphragmatic hernia is true?

- a. Conservative management produces a beneficial long-term outcome in nearly 100% of cases.
- b. Diaphragmatic hernia is incompatible with life; thus survival time with conservative management is several days at the most.
- c. Conservative management may work for the short term but does not produce a lasting good outcome.
- d. Conservative management is successful for returning to long-term full athletic performance.

2. Which approaches are useful for diaphragmatic herniorrhaphy?

- a. cranioventral midline and median sternotomy
- b. median sternotomy and flank and lateral thoracotomy
- c. cranioventral midline laparotomy and thoracoscopy or flank assisted lateral thoracotomy
- d. ventral midline laparotomy and flank-assisted median sternotomy

3. Which statement regarding hernia reduction is most accurate?

- a. Hernia reduction is most difficult when the liver and spleen are incarcerated.
- b. Enlarging the hernial ring, massaging the colon contents, and decompressing trapped air are useful measures to aid in safe intestinal reduction.
- c. Enlarging the hernial ring is counterproductive and should be avoided because it prevents secure closure and may result in profuse bleeding.
- d. Air decompression is the only procedure that aids in rapid, safe large colon reduction.

4. What surgical approach appears useful for common dorsal diaphragmatic defects?

- a. cranioventral midline
- b. left flank
- c. median sternotomy
- d. lateral rib-resection thoracotomy

5. Which statement is most accurate regarding herniorrhaphy techniques?

- a. Hernia closure should always be performed after intestinal resection because resection is more likely to be the limiting factor in surgery.
- b. Mesh should always be used to augment the repair.
- c. Herniorrhaphy should start at the most inaccessible region using preplaced sutures, synthetic mesh, extracorporeal knot tying, or other helpful modifications.
- d. Synthetic mesh should be placed intrathoracically to avoid intestinal abrasion, and nonabsorbable sutures should be used.

6. Which anesthetic changes characterize a horse with diaphragmatic hernia?

- a. deterioration following induction, hypoventilation leading to respiratory acidosis, hypoxemia, and difficulty in maintaining adequate plane of anesthesia
- b. dramatic decline in blood pressure combined with hypocarbia; immediate, deep plane of anesthesia following induction
- c. gradual decline in blood pressure combined with hypercarbia; rapid, deep plane of anesthesia
- d. marked hypercarbia and hypoxemia on induction;

immediate normalization after initiation of controlled mechanical ventilation

7. What postoperative management is indicated after diaphragmatic hernia repair?

- a. routine postoperative management of gastrointestinal surgery patient
- b. initial close monitoring of respiratory function, including arterial blood gas evaluation and thoracic radiography
- c. continuous thoracic evacuation using an indwelling rigid tube connected to a three-chamber drainage vacuum system
- d. all of the above

8. Which statement regarding postoperative complications of diaphragmatic hernia repair is most accurate?

- a. Most complications occur late in the rehabilitation period and inhibit future athletic activity.
- b. Immediate postoperative complications can be fatal, including bilateral pneumothorax, respiratory arrest, and recurrence or repair failure.
- c. Intraoperative complications are common and fatal, but postoperative complications after recovery are rare.
- d. Frequent postoperative complications include emphysema, pulmonary edema, septic pleuritis, and rib fractures.

9. Which factors seem to influence the success rate of diaphragmatic herniorrhaphy?

- a. age, breed, and gender; young quarter horse fillies have the best prognosis
- b. defect size, side, and shape; small, right-sided, linear tears have the best outcome
- c. hernial content and level of viability; nonstrangulating large colon lesions have the best prognosis
- d. defect location and age; fresh dorsal lesions appear to have a negative impact on successful repair

10. Which statement regarding prognosis after diaphragmatic hernia repair is most accurate?

- a. Prognosis is not as poor as previously described, especially with early diagnosis, a well-planned surgery, and intensive postoperative management.
- b. Survival following repair is likely, but return to athletic function is impossible.
- c. Survival of horses with diaphragmatic hernia is highly unlikely, even with prompt and proper care.
- d. With early surgical intervention, long-term survival and athletic function are expected in nearly 100% of admitted cases.